



Effects of Ag nanoparticles on the growth and spawning reproductive phases of the female Indian minor carp *Labeo bata*

Nilanjana Chatterjee^{1*}, Subir Mal² and Priyanka Halder Mallick²

¹Department of Zoology, Ramananda College, Bishnupur, Bankura, West Bengal, India

²Department of Zoology, Vidyasagar University, West Bengal, India
nilchat@gmail.com

Available online at: www.isca.in, www.isca.me

Received 4th April 2019, revised 22nd June 2019, accepted 30th June 2019

Abstract

The Ag nanoparticles synthesized in its cleanest form using fish bile has been administered in definite concentration upon *Labeo bata* exposed for different time periods. The fish exposed for greater time periods have been found to show marked changes in their liver histology as well as in the architecture of the ovarian tissue with reference to the different seasonal reproductive phases. Under controlled condition during the maturation phase of ovary the oocyte undergoing vitellogenesis have been found to increase in number as well as size leading to the production of yolk laden matured oocytes. On the contrary fish exposed for 3 to 4 weeks have been observed to show prolonged and most often incomplete vitellogenesis leading to the formation of a large number of late yolk vesicular stage oocytes ending up with the fate of atretic follicle formation.

Keywords: Ag nanoparticles, liver, ovary, histomorphology, *Labeo bata*.

Introduction

The present century has already earned the fame of being dominated by the use of nanotechnology. The boon of nanotechnology is the predominance of every possible sphere by engineered nanoparticles. According to an estimation approximately 60,000 tons of nanomaterials are produced every year¹. Several nano-materials including gold, silver, copper, etc. are widely used now a day for various purposes. Among these, silver nano materials are the widest used class with a production rate of 320 tons per annum². The increased use of these nanoparticles finally may end up in the aquatic environment^{3,4} posing the threat to several aquatic fauna⁵. The fitness and population densities of many aquatic organisms may also be altered due to the introduction of Ag-NPs in the aquatic ecosystem⁶. In spite of the wide use of nanoparticles no proper measures are taken for their proper disposal so they often end up in the water bodies' posing serious threat to the aquatic fauna⁵. Exposures to silver nanoparticles have been proved to be toxic for several aquatic fish⁷.

However, not much is known regarding the consequences of these engineered silver nanoparticles upon the edible carps. So, the purpose of the present study was to determine the changes if any in histomorphology of the most important organs of *Labeo bata*. It has been mentioned by few workers that silver nanoparticles have an adverse effect to the biotic component of the aquatic environment⁸⁻¹¹, including fish¹²⁻¹⁴. Indian minor carp *Labeo bata* (Hamilton, 1822) is an important nutritious fish of Asia adversely affected by silver nanoparticles which is shown by our previous study¹⁵. The aim of our present study is

to show the effect of Ag NPs to the reproductive potential and reproductive behavior of female *Labeo bata*.

Materials and methods

Synthesis of Ag NPs: Bile was collected from freshly sacrificed *Labeo rohita* weighing approximately 1kg, fetched from the local market of Paschim Medinipur, West Bengal, India. The collected bile was centrifuged and the supernatant was diluted to 5% with double distilled water.

5ml aliquot of fish bile extract was mixed with 5 ml aqueous solution of 0.1mM of silver nitrate. The mixture was exposed in microwave at 700W with 2450MHz frequency for 30 seconds. Yellow colour of various intensities developed depending upon the varying concentrations of AgNO₃ solutions from 0.1 Mm to 10 Mm representing the formation of Ag nanoparticles.

Characterization of silver nanoparticles: The silver nanoparticles have been characterized using UV-visible spectroscopy, Field Emission Scanning Electron Microscope (FESEM), X-ray diffraction Analysis (XRD), Higher Resolution Transmission Electron Microscope (HRTEM) and FTIR¹⁵.

Experimental set up: Four experimental tanks of 100 litre capacity each have been maintained with 15 female *Labeo bata* fish in each of them. In the first tank fishes were maintained under controlled conditions without application of any NPs. The second, third and fourth tanks were treated with NPs of concentration 100µg/L for a time period of 7, 14, 21 and 28 days.

Collection of tissues: The fish were caught from their natural habitats during the early maturation phase (March-April) and then acclimatized in the laboratory condition for 9 days before treating them with Ag NPs. The liver and kidney tissues were collected immediately after the fishes were sacrificed, cut into small pieces and then fixed in Bouin's fixative for 18 hours.

Tissue processing and staining: The tissues were dehydrated in ascending series of ethanol, cleared in xylene and embedded in paraffin (56°C-58°C) for transverse serial sections of 4 μm thicknesses. The obtained sections were stained using Haematoxylin and Eosin (HE) and Mallory's triple stain^{16,17}.

Tissue observation: The stained tissues were observed under microscopes and photographed using a camera attachment (Leica).

Results and discussion

After an exposure to our synthesized Ag NPs of concentration of 100 $\mu\text{g/L}$ for a period of 7, 14, 21 and 28 days the histology of the liver and ovary of the fish has revealed the following characteristics:

Hepatic Tissue (Liver): The liver under controlled condition contains round or polygonal hepatocytes bearing prominent nuclei (Figure-1A). The liver of fish being exposed for 7 days has been found to contain hepatocytes of normal size (12 μm -16 μm diameter) with centrally placed uni-nucleated cells containing distinct nucleoli. Regular blood vessels have been traced in near proximity to the hepatocytes during the maturation phase of the reproductive cycle (Figure-1B). However, the fish exposed for a period of 14 days have shown some inflated binucleated hepatocytes with slight disarray in the hepatic cords. (Figure-1C). With further exposure for 7 days (21 days exposure), larger number of binucleated hepatocytes have been noticed with lipid vacuolization and increase in the sinusoidal spaces in between the altered hepatic cords. Prominent blood congestion forming islands in the tissue matrix were not uncommon (Figure-1E). Cloudy swelling of hepatocytes with hemorrhagic sites was seen in fish with 28 days exposure time. Small foci of necrosis and apoptotic changes have also been traced leading to the disarray of long hepatic cords. Irregular shaped nuclei, nuclear hypertrophy, nuclear vacuolization have been noticed. Some eosinophilic granules have also been traced in the hepatic cytoplasm along with indications of karyomegaly. In the extremity pyknotic nuclei and cytolysis of the hepatocytes have also been observed. The hepatic sinusoidal spaces continued to increase with markedly visible empty spaces in between hepatic cords owing to cellular necrosis (Figure-1F).

Ovarian Tissue: The fishes upon exposure to Ag NPs for a time period of 7, 14, 21 and 28 days have been sacrificed for the collection of the ovarian tissue. The ovary under controlled condition bared large number of yolk laden matured ovum distinctly separated and connected by outer zona radiata and

inner zona granulosa layers (Figure-2A). The ovary exposed for 7 days in the month of April have shown normal development with signs of the onset of the vitellogenesis process during the late April. The yolk vesicles were prominent with traces of yolk deposition in the centripetal fashion. The late maturation period ovary showed the presence of large number of matured ovum with eccentrically placed nucleus. (Figure-2B). The ovaries with 14 days exposure have shown oocytes which were much reduced in size compared to that of the fish under control. The vitellogenesis was of spatial occurrence. However, the fish exposed for 21 days have shown almost no trace of vitellogenesis even in the latter half of May (Figure-2D), which otherwise is the period of prime maturation for the oocytes of the fish under control. The vitellogenesis is almost completed during this period in case of the controlled fish and large number of yolk laden mature oocytes with eccentric nuclei is visible (Figure-2C). The oocytes of the treated fish have shown almost insignificant vitellogenesis. The value of the volume of nucleus (n) to cytoplasmic (c) ratio of the oocyte remains higher and equalizes with the value of the early yolk vesicular stage (Figure-2D). Large number of atretic follicles has been observed in the ovary of the fish that were under Ag NP exposure for 3 weeks and more (28 days) (Figure-2E). Some of the oocytes that managed to incorporate yolk materials even after treatment for 14 days failed to stay stable ended up in atresia (Figure-2F). The nuclear membranes have shown irregular outlines with coalescing nucleoli (Figure-E).




Figure-1A: Under controlled condition the hepatocytes (Hc) show round or polygonal cells bearing one prominent nuclei. The hepatocytes are arranged in distinct array. Note the presence of fat vacuoles (Fv) intercalated in between the Hc during the maturation phase (May). The blood cells (Bc) are located in close proximity to the hepatocytes. [HE-Haematoxylin and Eosin].

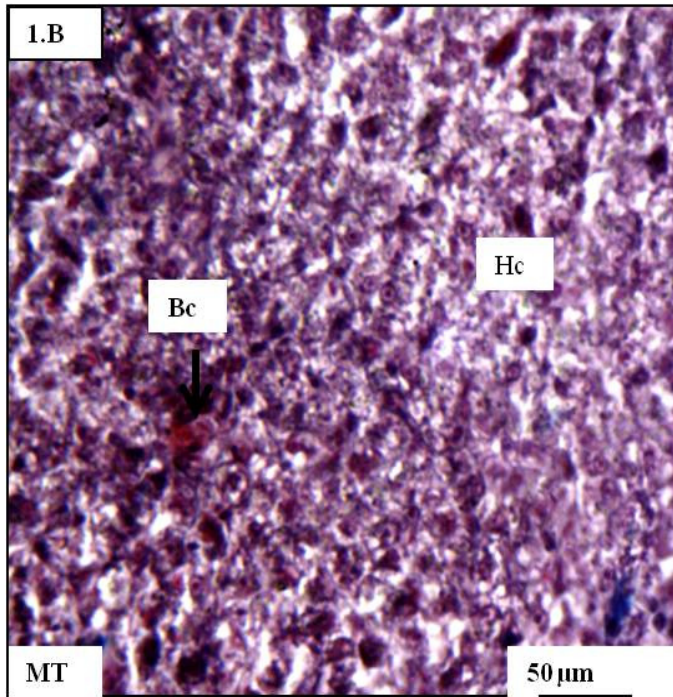


Figure-1B: The hepatic tissue with an exposure period of 7 days showing distinct Hc with blood cells in close proximity. [MT-Mallory's triple stain].

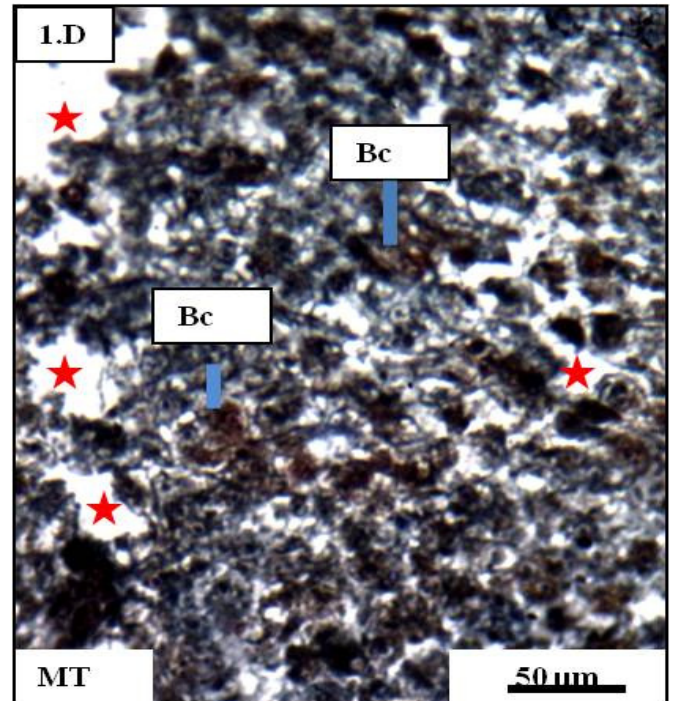


Figure-1C and D: The hepatic chords show slight disarray with large number of empty spaces (red stars). Also note the large number of Bc in between the disrupted hepatic chords.

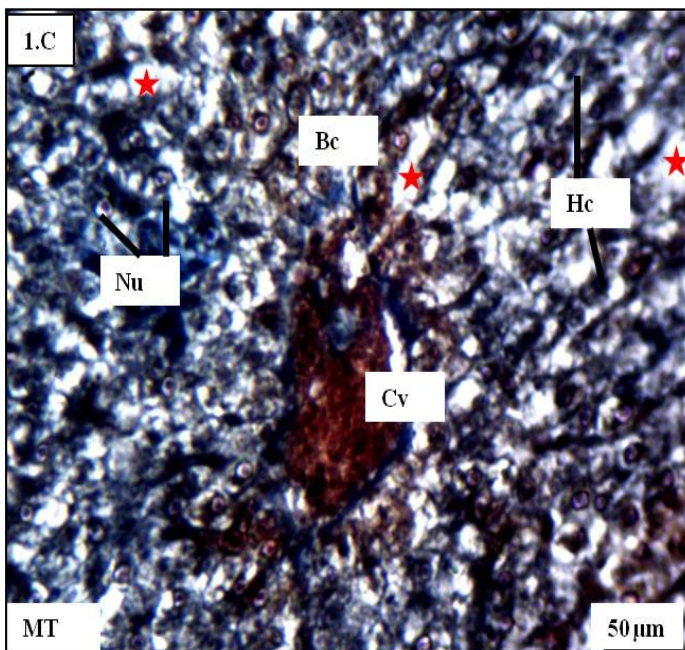


Figure-1C: The hepatic tissue with an exposure period of 14 days show inflated hepatocytes (Hc). Most of the hepatocytes show bi-nucleated (Nu) condition. Large numbers of empty spaces are detected in between the hepatocytes (red stars). A prominent central vein is present (Cv) which again spreads its blood cells (Bc) in its periphery.

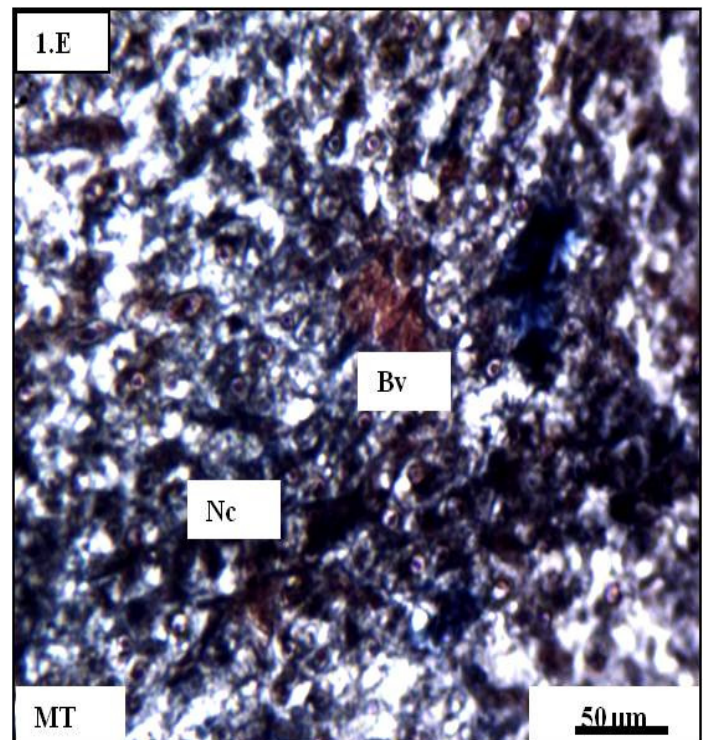


Figure-1E: Prominent blood congestion (Bv) is noticed with large number of surrounding necrotic cells (Nc) bearing lump of shrunk anucleated cellular mass.

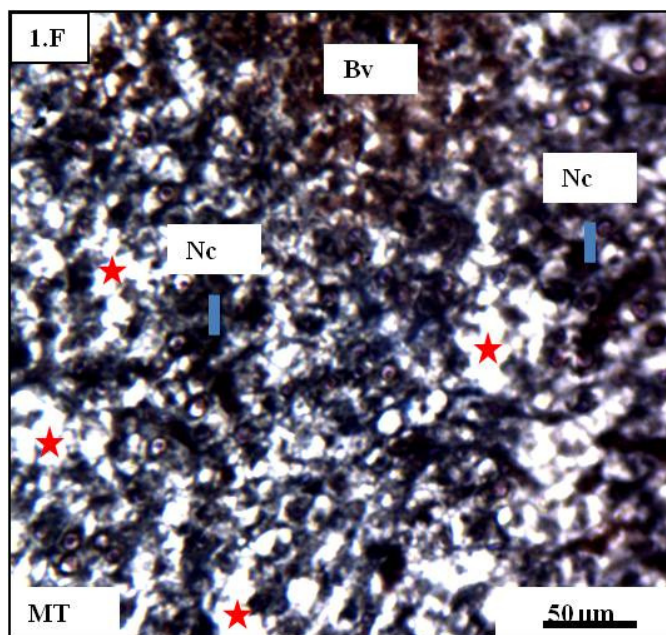


Figure-1F: Prominent blood vessel (Bv) is present with large number of empty spaces (red stars). Darkly stained necrotic cells (Nc) are observed which are giving rise to empty spaces.

Figure-1A to Figure-F: Photomicrographs of the histology of liver of *Labeo bata* during the maturation phase of its seasonal reproductive cycle (April-May);

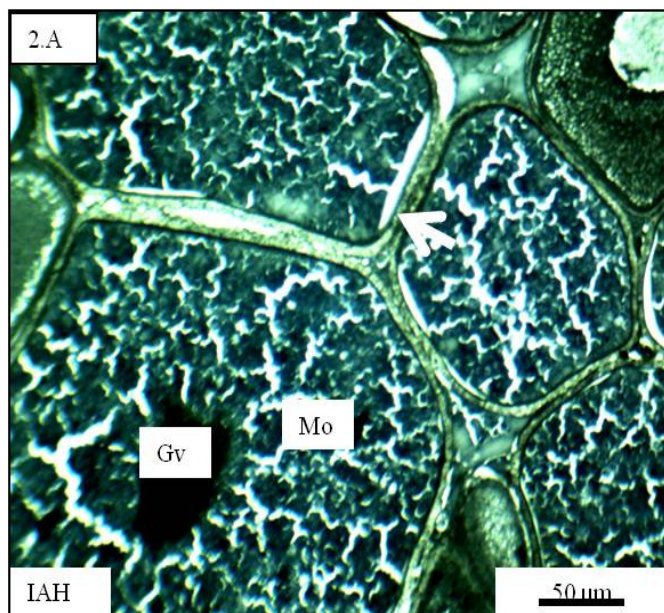


Figure-2A: Ovary under controlled condition bearing large number of mature ovum (Mo) with distinct germinal vesicle (Gv). Note that the Mo are connected and separated by the combined zona radiata and zona granulosa layers shown by white arrow. [IAH-Iron Alum Haematoxylin]

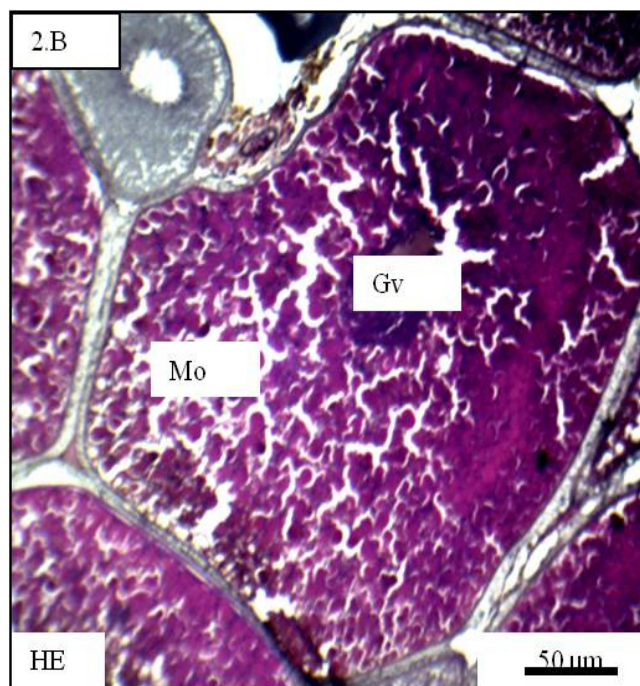


Figure-2B: The ovary exposed for 7 days in late maturation period showed the presence of large number of matured ovum with eccentrically placed nucleus and fewer early oocytic stages in between. [HE-Haematoxylin and Eosin stain]

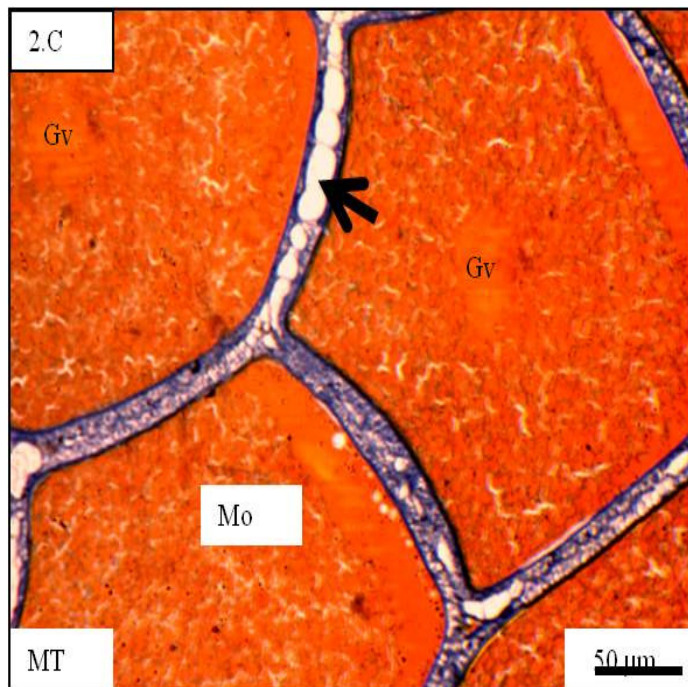


Figure-2C: An ovary with 7 days Ag NPs exposure show distinct zona layers (black arrow) encircling the yolk laden matured follicles (Mo) with visible germinal vesicle (Gv). [MT-Mallory's Triple stain]

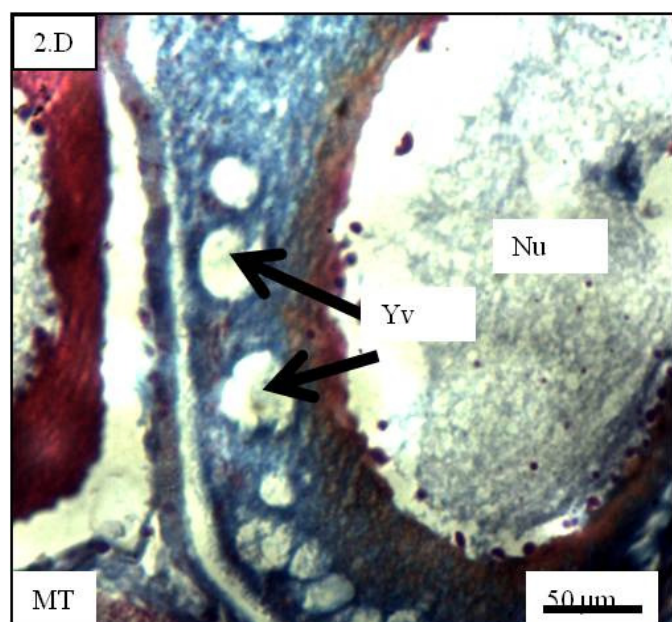


Figure-2D: An ovary with 21 days Ag NPs exposure shows oocytes with large yolk vesicles (Yv) with no trace of vitellogenesis. Note that the nucleus (Nu) is much larger in size with few visible nucleoli and the cytoplasmic zone containing Yv around the nucleus is very thin.

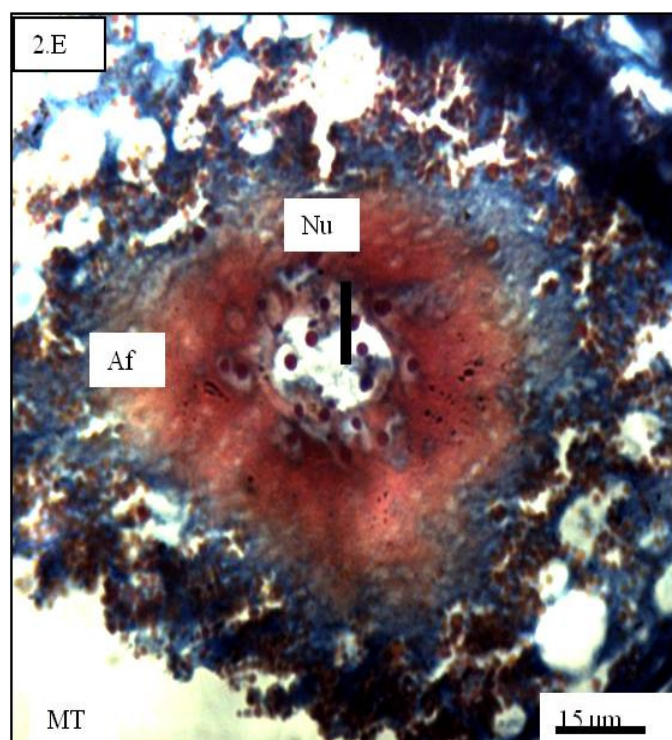


Figure-2E: A follicle undergoing atresia (af), after 28 days of AgNPs exposure with collapsing nuclei (Nu). Note that the cytoplasm contains traces of yolk granules that are convoluting in the nuclear periphery with coalescing nucleoli.

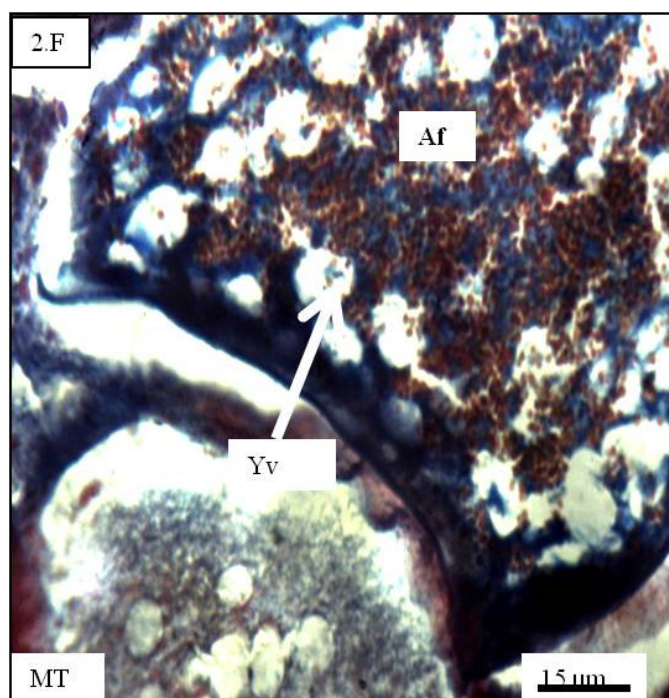


Figure-2F: An oocyte with 14 days Ag NPs exposure showing atresia (Af) after moderate yolk incorporation. Note that most of the yolk vesicles (Yv) are still prominent. The outer zona layers are receding from the adjacent follicles.

Figure-2A to Figure-2F: Photomicrographs of the histology of the ovary of *Labeo bata* during the maturation phase of its seasonal reproductive cycle (April-May);

Discussion: The hepatocytes possess the ability to metabolize, detoxify and inactivate exogenous compounds. Hence, the binucleated condition of some of the hepatocytes and increased size of the cells under experimental conditions may be due to the hyperactivity of the hepatocytes against some unfavourable physiological conditions leading to cell damage and necrosis. This can further be confirmed from the irregular and disrupted hepatic chords. On the other hand, the higher value of the ratio of 'n' and 'c' indicates diminished cytoplasmic growth during the maturation phase and arrest of the oocytes in their early and middle yolk vesicular stage. On Ag NP exposure for longer period, the vacuolization of the hepatocytic cytoplasm in comparison to control group may have resulted due to some toxic effect of these Ag NPs.

Metabolic stress may again be confirmed by the failure of vitellogenesis in the yolk vesicular stage oocytes. The probable reason may be attributed for the changes in the metabolic activities of the fish during the maturation phase of the oocytes. In *Channa punctatus* the ovary and other vital organ were affected by hexavalent chromium and eventually reproductive system was found to be completely lacking¹⁸. Chatterjee *et al.*¹⁹ showed that ZnS nanoparticles affect hazarously the process of

oogenesis in *Mystus vittatus*. The liver under altered physiological conditions perhaps fails or prefers not to synthesize the vitellogenin that ends up depositing in the yolk vesicles of the maturing oocytes. This finally leads to a “no spawning” state of the mature adult female. This is interestingly a survival strategy of the fish under stressful or unfavorable condition. When Bluegill sunfish were exposed to endosulfan, the ovaries were detected with empty follicles along with necrosis of nuclei and atretic cells²⁰. Wang found TiO₂ nanoparticles to be responsible for the changes in the optimum environmental condition of water and disruption of reproduction of *Danio rerio*²¹. The exposure to the Ag NPs may also lead to the decrease in the production of the ovarian proteins as already revealed in case of treatment with Mercuric chloride²². The changed environmental condition of the fish may also send some cue to the sensory cells of the pituitary affecting the gonadotropin levels in the pituitary gland and eventually ceasing the gonadal development as verified by Harris *et al.* in case of nonylphenol²³. Under unfavorable physiological condition, the first aim of any living being is to maintain stability and survive in that environment with minimum metabolic activity. So the reproductive behavior is temporarily ceased by the fish until the appearance of favourable environmental conditions.

Conclusion

Our experiment with the Ag NPs on *Labeo bata* have revealed that on prolonged exposure for about a month, the mature adult females have faced serious threat as far as their normal seasonal reproductive activity is concerned. The hepatic histology have revealed serious loss in the reserved fat and glycogen vacuoles along with hepatic chord disarray thus depicting violation of the regular metabolic activities which is reflected astonishingly in the immature oocytic cells. Oocytes have failed to undergo vitellogenesis during the potential maturation and spawning phases thus arresting in their growth phase of reproduction.

The Ag NPs that end in the water bodies enter the fish body resulting into altered metabolic activity thus leading into cessation of the normal spawning of *L. bata*. Thus, appropriate measures should be taken for the proper disposal of harmful nanoparticles so that they may not end up in the aquatic bodies affecting the fish.

Acknowledgement

The authors would like to convey their thanks to the Department of Zoology, Ramananda College, Bishnupur, Bankura, India and Vidyasagar University, Paschim Medinipur, India for extending their cooperation and necessary infrastructure during the tenure of this research.

References

1. Jovanović B., Anastasova L., Rowe E.W., Zhang Y., Clapp A.R. and Palić D. (2011). Effects of nanosized titanium dioxide on innate immune system of fathead minnow (*Pimephales promelas* Rafinesque, 1820). *Ecotoxicology and Environmental Safety*, 74(4), 675-683. <https://doi.org/10.1016/j.ecoenv.2010.10.017>
2. Nowack B., Ranville J.F., Diamond S., Gallego-Urrea J.A., Metcalfe C., Rose J., Horne N., Koelmans A.A. and Klaine S.J. (2012). Potential scenarios for nanomaterial release and subsequent alteration in the environment. *Environmental Toxicology and Chemistry*, 31(1), 50-59. <https://doi.org/10.1002/etc.726>
3. Benn T.M. and Westerhoff P. (2008). Nanoparticle silver released into water from commercially available sock fabrics. *Environmental Science and Technology*, 42(11), 4133-4139. <https://doi.org/10.1021/es7032718>
4. Taju G., Majeed S.A., Nambi K.S.N. and Hameed A.S. (2014). In vitro assay for the toxicity of silver nanoparticles using heart and gill cell lines of *Catla catla* and gill cell line of *Labeo rohita*. *Comparative Biochemistry and Physiology Part C: Toxicology & Pharmacology*, 161, 41-52. <https://doi.org/10.1016/j.cbpc.2014.01.007>
5. Moore M.N. (2006). Do nanoparticles present ecotoxicological risks for the health of the aquatic environment?. *Environment International*, 32(8), 967-976. <https://doi.org/10.1016/j.envint.2006.06.014>
6. Luoma Samuel N. and Rainbow Philip S. (2008). Metal Contamination in Aquatic Environments Science and Lateral Management. Cambridge University Press, Cambridge. ISBN: 9780521860574
7. Griffitt R.J., Luo J., Gao J., Bonzongo J.C. and Barber D.S. (2008). Effects of particle composition and species on toxicity of metallic nanomaterials in aquatic organisms. *Environmental Toxicology and Chemistry*, 27(9), 1972-1978. <https://doi.org/10.1897/08-002.1>
8. Kennedy A.J., Hull M.S., Bednar A.J., Goss J.D., Gunter J.C., Bouldin J.L., Vikesland P.J. and Steevens J.A. (2010). Fractionating nanosilver: importance for determining toxicity to aquatic test organisms. *Environmental Science and Technology*, 44(24), 9571-9577. <https://doi.org/10.1021/es1025382>
9. Navarro E., Piccapietra F., Wagner B., Marconi F., Kaegi R., Odzak N., Sigg L. and Behra R. (2008). Toxicity of silver nanoparticles to *Chlamydomonas reinhardtii*. *Environmental Science and Technology*, 42(23), 8959-8964. <https://doi.org/10.1021/es801785m>
10. Yang X., Gondikas A.P., Marinakos S.M., Auffan M., Liu J., Hsu-Kim H. and Meyer J.N. (2011). Mechanism of silver nanoparticle toxicity is dependent on dissolved silver and surface coating in *Caenorhabditis elegans*. *Environmental Science and Technology*, 46(2), 1119-1127. <https://doi.org/10.1021/es202417t>

11. Zhang W., Xiao B. and Fang T. (2018). Chemical transformation of silver nanoparticles in aquatic environments: Mechanism, morphology and toxicity. *Chemosphere*, 191, 324-334. <https://doi.org/10.1016/j.chemosphere.2017.10.016>
12. Hedayati A., Kolangi H., Jahanbakhshi A. and Shaluei F. (2012). Evaluation of silver nanoparticles ecotoxicity in silver carp (*Hypophthalmichthys molitrix*) and goldfish (*Carassius auratus*). *Bulgarian Journal of Veterinary Medicine*, 15(3), 172.
13. Hedayati A., Shaluei F. and Jahanbakhshi A. (2012). Comparison of toxicity responses by water exposure to silver nanoparticles and silver salt in common carp (*Cyprinus carpio*). *Global Veterinaria*, 8(2), 179-184. [http://www.idosi.org/gv/GV8\(2\)12/14.pdf](http://www.idosi.org/gv/GV8(2)12/14.pdf)
14. Scown T.M., Santos E.M., Johnston B.D., Gaiser B., Baalousha M., Mitov S., Lead J.R., Stone V., Fernandes T.F., Jepson M. and van Aerle R. (2010). Effects of aqueous exposure to silver nanoparticles of different sizes in rainbow trout. *Toxicological Sciences*, 115(2), 521-534. <https://doi.org/10.1093/toxsci/kfq076>
15. Mal S., Bar H. and Chatterjee N. (2018). Effect of Ag nanoparticles on the hepatic and renal histomorphology of the Indian minor carp *Labeo bata*. *International Journal of Basic and Applied Research*, 8(12), 508-518.
16. Avwioro O.G. (2010). *Histochemistry and tissue pathology, principles and techniques*. Claverianum press, Nigeria.
17. Mallory F.B. (1936). The aniline blue collagen stain. *Stain Technology*, 11(3), 101-102.
18. Mishra A.K. and Mohanty B. (2008). Histopathological effects of hexavalent chromium in the ovary of a fresh water fish, *Channa punctatus* (Bloch). *Bulletin of Environmental Contamination and Toxicology*, 80(6), 507-511. <https://doi.org/10.1007/s00128-008-9406-9>
19. Chatterjee N. and Bhattacharjee B. (2016). ZnS nanoparticles affect hazardously the process of oogenesis in the dwarf Asian striped catfish *Mystus vittatus* (Bloch, 1794). *Advanced Science Letters*, 22(1), 126-131. <https://doi.org/10.1166/asl.2016.6789>
20. Dutta H.M. and Dalal R. (2008). The Effect of Endosulfan on the Ovary of Bluegill Sunfish: A Histopathological Study (*Lepomis macrochirus*). *International Journal of Environmental Research*, 2(3), 215-224.
21. Wang J., Zhu X., Zhang X., Zhao Z., Liu H., George R., Wilson-Rawls J., Chang Y. and Chen Y. (2011). Disruption of zebrafish (*Danio rerio*) reproduction upon chronic exposure to TiO₂ nanoparticles. *Chemosphere*, 83(4), 461-467. <https://doi.org/10.1016/j.chemosphere.2010.12.069>
22. Saksena D.N. and Agarwal A. (1991). Effect of mercuric-chloride on certain biochemical-constituents of the ovary of Indian fresh-water Catfish, *Clarias batrachus* (Linn). *Journal of Advanced Zoology*, 12(1), 13-18.
23. Harris C.A., Santos E.M., Janbakhsh A., Pottinger T.G., Tyler C.R. and Sumpter J.P. (2001). Nonylphenol affects gonadotropin levels in the pituitary gland and plasma of female rainbow trout. *Environmental Science and Technology*, 35(14), 2909-2916. <https://doi.org/2909-2916.10.1021/es0002619>