



Immunohistochemical Expression of Fn14 in Invasive Ductal Carcinoma (IDC) and its Correlation with Clinical and Histopathological parameters of Human Breast Cancer

EL-Fiky Sh.M.¹, Yahia M.A.¹, AL Sedfy A.S.² and AL-Qadasi S.A.¹

¹Dept. of Histochemistry and Cell Biology, Medical Research Institute, Al Ibrahimiyah, Alexandria University, Alexandria, EGYPT

²Dept. of Pathology, Medical Research Institute, Al Ibrahimiyah, Alexandria University, Alexandria, EGYPT

Available online at: www.isca.in, www.isca.me

Received 28th January 2015, revised 15th February 2015, accepted 27th February 2015

Abstract

Fibroblast growth factor-inducible 14 (Fn14), is a member of the tumor necrosis factor receptor superfamily that normally expressed in healthy tissues, but its expression is increased in injured tissue where it thought to play role in tissue remodeling. Over expression of Fn14 expression is reported in many tumors, which is why this protein is under consideration as a therapeutic target in oncology. The aim of the present work was to investigate the expression of Fn14 as a novel prognostic biomarker in human invasive ductal carcinoma (IDC) versus benign tumors and normal breast tissues as well as their correlation with different pathological and histological parameters. Immunohistochemical technique was used to examine the expression of Fn14 in normal, benign as well as in IDC. Present results showed higher expression of Fn14 in IDC comparing to normal and benign breast tissues. Statistical analysis showed significant correlations between the expression of Fn14 and histological tumor grade, lymph node metastasis (LNM) and HER2/neu. Negative correlation was noticed between the expression of Fn14 and both ER and PR status. Current results suggest that Fn14 protein may be a valuable prognostic and therapeutic marker inhuman IDC pateints.

Keywords: Fn14, IDC, IOD, HER2/neu, prognostic marker.

Introduction

Breast cancer represents a major scientific, clinical and societal problem. It is the most common malignancy and the second leading cause of cancer death in females following lung cancer^{1,2} with more than 1,000,000 new cases and 370,000 deaths yearly worldwide³. In many developing countries, the incidence of breast cancer is now rising sharply due to changes in reproductive factors, lifestyle, and increased life expectancy⁴.

Fibroblast growth factor-inducible-14 (Fn14) is the smallest member of the tumor necrosis factor (TNF) super family of receptors identified so far⁵. It is a type I trans-membrane receptor of a tumor necrosis factor likes weak inducer of apoptosis (TWEAK). Fn14 binding to its ligand (TWEAK) induces receptor trimerization, tumor necrosis factor receptor-associated factors (TRAF) association with the cytoplasmic tail and activation of intracellular signaling cascades such MAPK, and NF- κ B which seems to be a universal cellular response⁶.

Fn14 is expressed at relatively low levels in normal tissues, but its expression is elevated in injured tissues, where it plays a role in tissue remodeling⁶. Its expression is detectable in a number of tumor types, including breast⁷, pancreas⁸, esophagus⁹ and brain¹⁰, where it appears to have a role in the invasive potential of these diseases¹¹. It has been reported that Fn14 stimulates cell proliferation, migration and differentiation⁶. Therefore, further studies are required to clarify the expression of Fn14 in breast

tumors and its correlation with different pathological and histological parameters of the breast cancer.

In the present study, expression of Fn14 in an invasive ductal carcinoma (IDC) was investigated using immunohistochemical technique and the intensity of Fn14's immunostaining was quantitatively estimated using image optical density (IOD) analyzer.

Material and Methods

Tissue samples were obtained from patients diagnosed with breast tumors in the Department of Pathology, Medical Research Institute, Alexandria University, Egypt, during September 2013 to April 2014. Formalin-fixed and paraffin embedded tissue specimens from 60 patients diagnosed with IDC, 30 patients diagnosed with benign breast tumor and 10 were taken from normal breast tissue adjacent to the tumors were included. All the cases were asked to freely volunteer to the study and informed written consents were gathered prior to their inclusion in the study. Hematoxlin and eosin (H&E) stained slides for each patient were reviewed by two pathologists. Diagnosis of the specimens was made according to the WHO classification of the Tumors. Clinical parameters included patients' age, tumor size, lymph node metastasis (LNM) status and biological markers (ER, PR, and HER2/neu).

Immunohistochemical investigation of Fn14:

Immunohistochemical method was utilized to study the expression of Fn14 in 100 paraffin-embedded breast tissues. In brief, paraffin-embedded specimens were cut into 5µm thick sections. The sections were deparaffinized using 2 changes of xylene and rehydrated. The sections were submerged in an antigen retrieval (citrate buffer saline pH 6) in an oven at 95°C for 20 minutes and then left at room temperature for 20 minutes to cool. The sections were treated with 3% H₂O₂ in PBS to quench the endogenous peroxidase activity, and then incubated with serum blocking reagent for 30 minutes to block nonspecific binding. The sections were incubated with primary antibody for Fn14 (Biorbyt Company, London, UK) at 4°C overnight. Sections were treated with conjugated 2nd antibody (ABC-HRP reagent) for 30 minutes, stained with diaminobenzidine (DAB) and counter stained with hematoxin. For negative controls, antibody was replaced with PBS. Each step was followed by PBS washing. Evaluation of Fn14' simmunohistochemical results was arbitrarily graded as negative (0), weak (+1), moderate (+2) and strong (+3).

Image analysis: Integrated optical density (IOD) of Fn14 in normal, benign and IDC groups was analyzed using digital image analyzer. Images were viewed and recorded using Olympus microscope equipped with spot digital camera and

image J software. Maximum, minimum and integrity of intense color based on Gray-level acquisition and analysis of the data were carried out by reading 10 fixed areas in one image for each case. The mean values of each reaction were based on the mean of pixel number¹³. IOD based on Gray-level transition probabilities in digitized images was graded from dark to light (250 up to 0).

Statistical Analysis: Data were normally distributed according to the Kolmogorov-Smirnov (K-S) normality test, and then analyzed using statistical software package SPSS 20. P values ≤ 0.05 were considered statistically significant.

Results and Discussion

Immunohistochemical reactivity of Fn14: Immunostaining reactivity of Fn14 was detected as granular brown stain observed in the cytoplasm and cytomembrane of the ductal epithelial cells of the studied groups. Fn14 immunostaining reactivity was negative (-ve) in 70% (7/10) of control breast tissues, weak (+1) in 70% (21/30) of benign group, while it was moderate (+2) in 78%(35/45) of IDC grade II and strong (+3) in 77% (10/13) of IDC grade III (grade I was represented by 2 cases only, therefore, it was excluded) table 1 and figures 1.

Table-1
Immunostaining reactivity of Fn14 in normal, benign and IDC groups

Fn14	Control group		Benign group		IDC group				Total	
					Grade II		Grade III			
	No	%	No	%	No	%	No	%	No	%
Negative (-ve)	7	70	6	20	2	4	0	0	16	16
Weak (+1)	3	30	21	70	3	7	1	8	37	38
Moderate (+2)	0	0	2	7	35	78	2	15	32	33
Strong (+3)	0	0	1	3	5	11	10	77	13	13
Total	10	100	30	100	45	100	13	100	98	100

$\chi^2 = 118, p = 0.000$ (statistically significant)

χ^2 : Chi square test

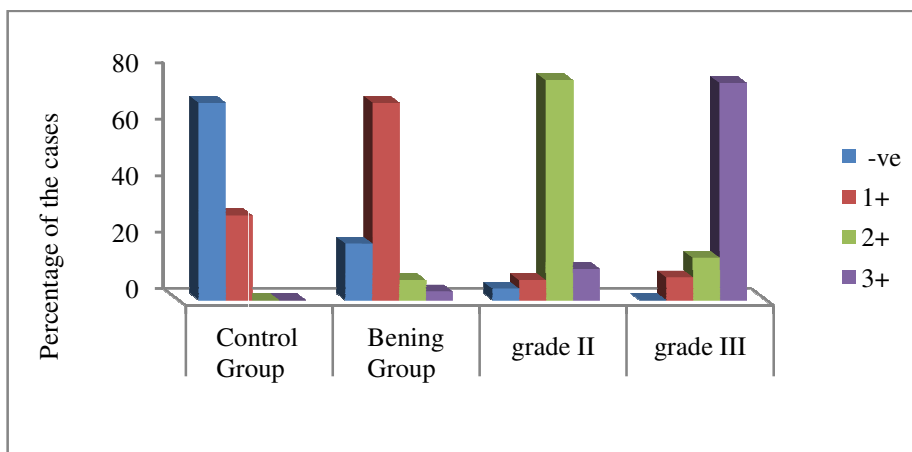


Figure-1

Immunostaining reactivity of Fn14 in the different studied groups. Fn14 was overexpressed in IDC versus control and benign groups

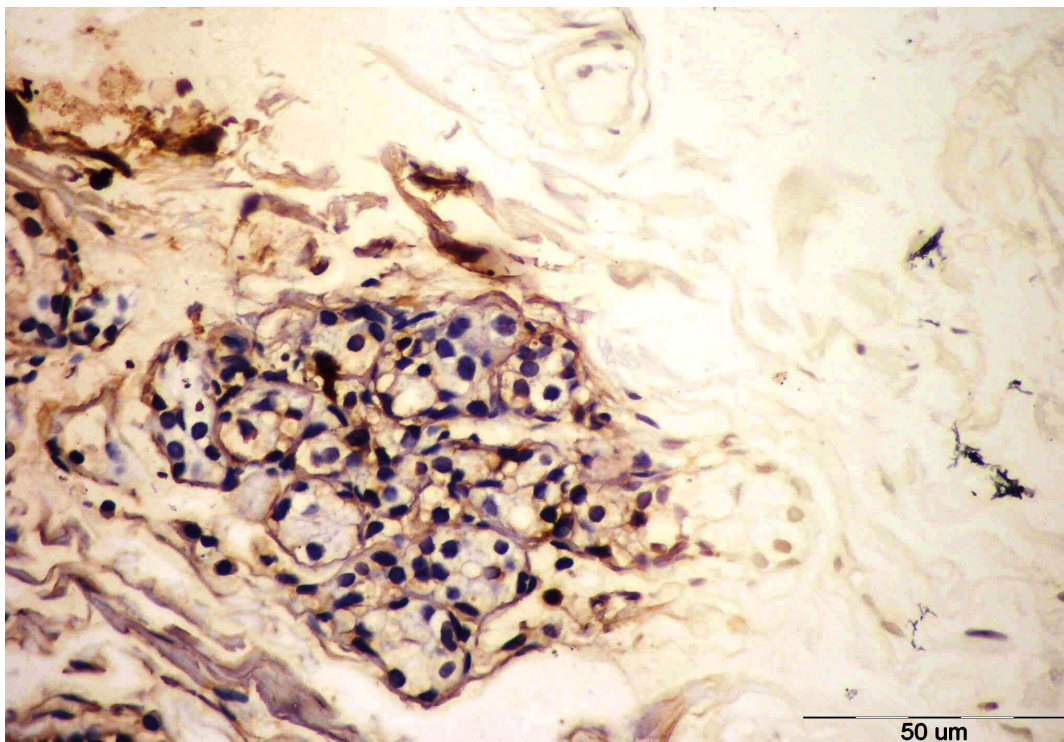


Figure-2

A normal breast tissue showing negative (-ve) expression of Fn14 in the cytoplasm of the ductal epithelial cells (Bar =50 μ m)

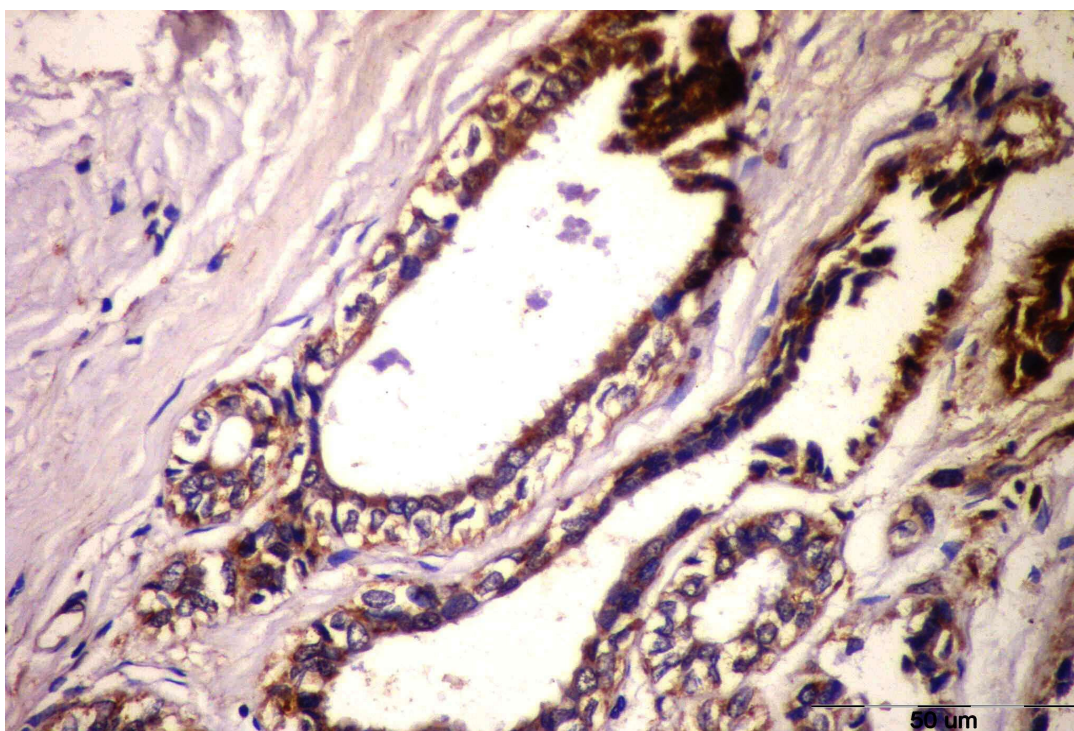


Figure-3

A benign breast tissue showing weak (+1), granulated and membranous expression of Fn14 in the myoepithelial and ductal cells (Bar =50 μ m)

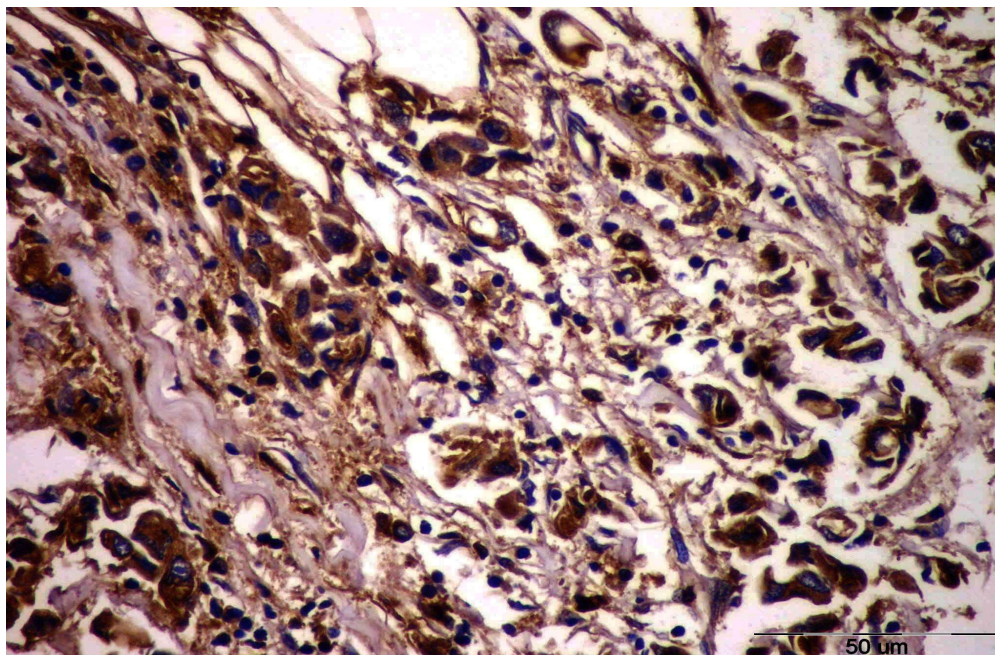


Figure-4

An IDC grade II breast tissue showing moderate (+2) expression of Fn14 in the cytoplasm of the ductal epithelial cells (Bar =50 μm)

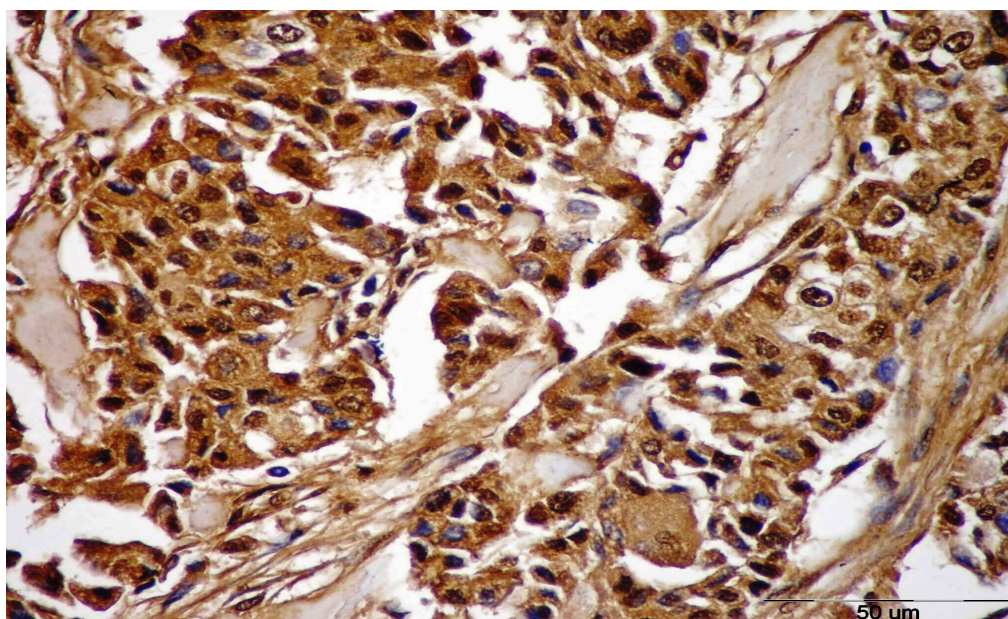


Figure-5

An IDC grade III breast tissue showing strong (+3) granulated, cytoplasmic and membranous expression of Fn14 in the ductal epithelial cells (Bar =50 μm)

Integrated optical density (IOD) of Fn14 in the different studied groups: The mean values of Fn14's IOD of control, benign and IDC grade II and III were 27 ± 3 , 32 ± 4 , 136 ± 6 and 156 ± 4 respectively. A significant difference was noticed between the expression of Fn14 in IDC (grade II and III) and the

expression of Fn14 in both normal and benign groups ($p < 0.00$), but there was no statistical significant difference between the expression of Fn14 in normal and benign groups ($p = 0.1$) as illustrated in table 2 and figure 6.

Table-2
The mean and SD of the IOD of Fn14 in normal, benign and IDC groups

Fn14	Control (n = 10)	Benign (n = 27)	Grade II (n = 40)	Grade III (n = 12)	F	p
Min. – Max.	24– 33	24 – 38	127– 146	149– 165	3991	<0.001*
Mean ± SD.	27 ± 3	32 ± 4	136 ± 6	156 ± 4		
p ₁		0.1	<0.001*	<0.001*		
p ₂			<0.001*	<0.001*		
p ₃			<0.001*			

F: F test (ANOVA), p₁ : p value for Post Hoc test (Scheffe) for comparing between control and each other group, p₂ : p value for Post Hoc test (Scheffe) comparing between benign and each other group, p₃ : p value for Post Hoc test (Scheffe) for comparing between grade II with grade III, *: Statistically significant at the 0.05 level

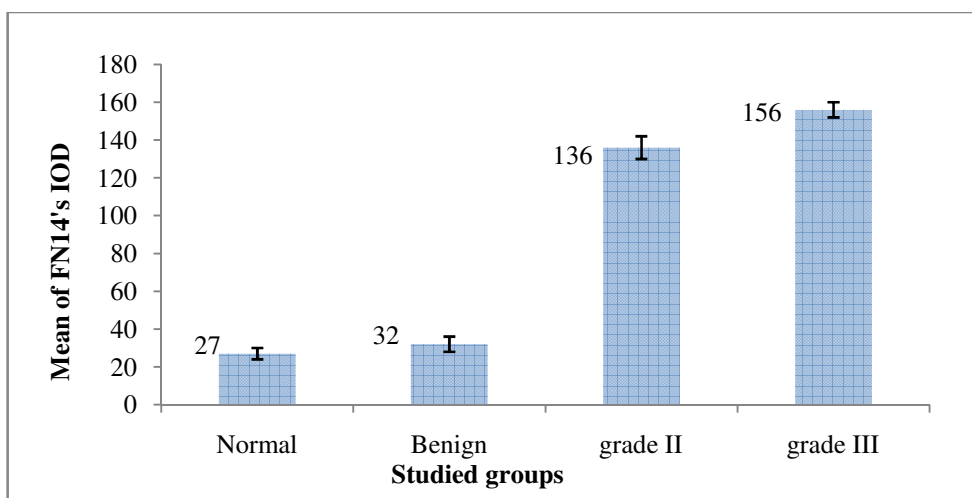


Figure-6
The mean and SD of Fn14's IOD in normal, benign and IDC groups

Correlation between IOD of Fn14 and histopathological parameters of breast cancer: There was no statistical significant correlation between the expression of Fn14 and patient's age ($r = -.03, P = 0.8$) and tumor size ($r = .246, P = .06$) of the studied groups' cases, while a statistical significant correlation was noticed between LNM and the expression of

Fn14 ($r = .28^*, P = .03$). A statistically significant negative correlation was observed between the expression of Fn14 and both ER and PR ($r = - 0.3, P = .03^*$) status, while a highly statistical significant correlation was noticed between the expression of Fn14 and tumor grade ($r = .755^{**}, P < .001$) and HER2/neu status ($r = .535^{**}, p < .001$) as shown in table-3.

Table-3
Correlation between IOD of Fn14 and histopathological parameter of breast cancer

Pathological parameters	Fn14 IOD	
	r	p
Age	r	-0.03
	p	0.82
Tumor size	r _s	.246
	p	.058
Grades	r _s	.755**
	p	.000
LNM	r _s	.283*
	p	.030
ER status	r _s	-0.276 *
	p	.033
PR status	r _s	-0.279 *
	p	.031
HER2/status	r _s	.535**
	p	.000

r: Pearson coefficient, r_s: Spearman coefficient, * Correlation is significant at the 0.05 level, ** Correlation is significant at the 0.01 level.

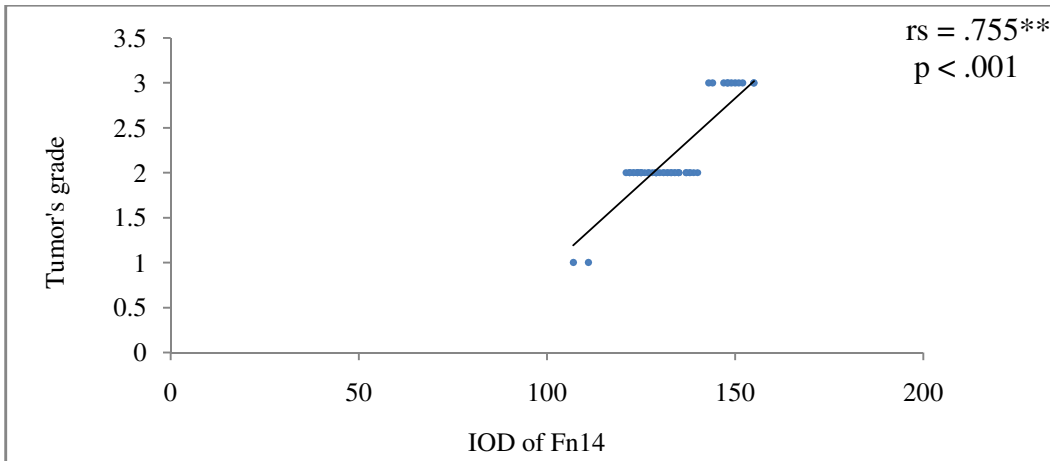


Figure-7
Correlation between IOD of Fn14 and tumor's grade of the breast cancer cases

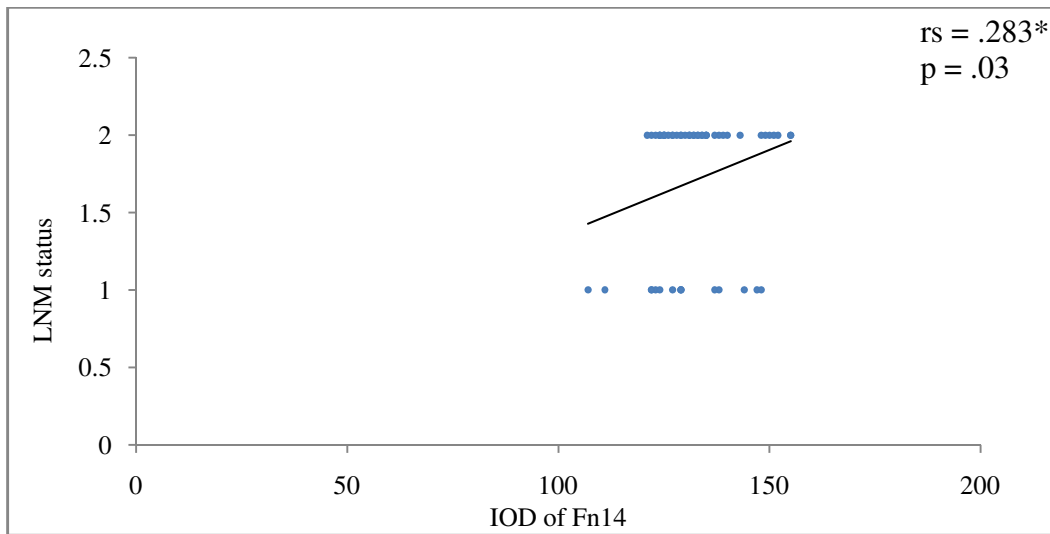


Figure-8
Correlation between IOD of Fn14 and LNM status of breast cancer cases

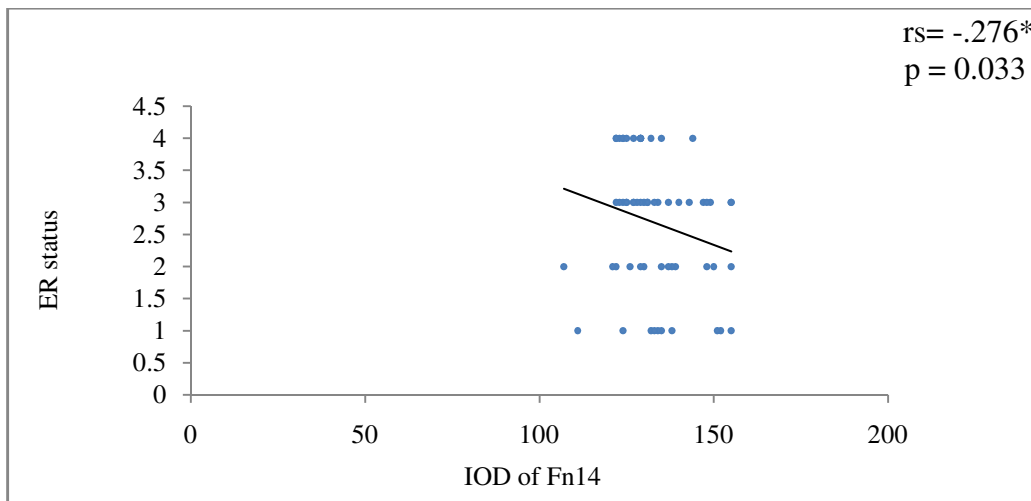


Figure-9
Correlation between IOD of Fn14 and ER status of breast cancer cases

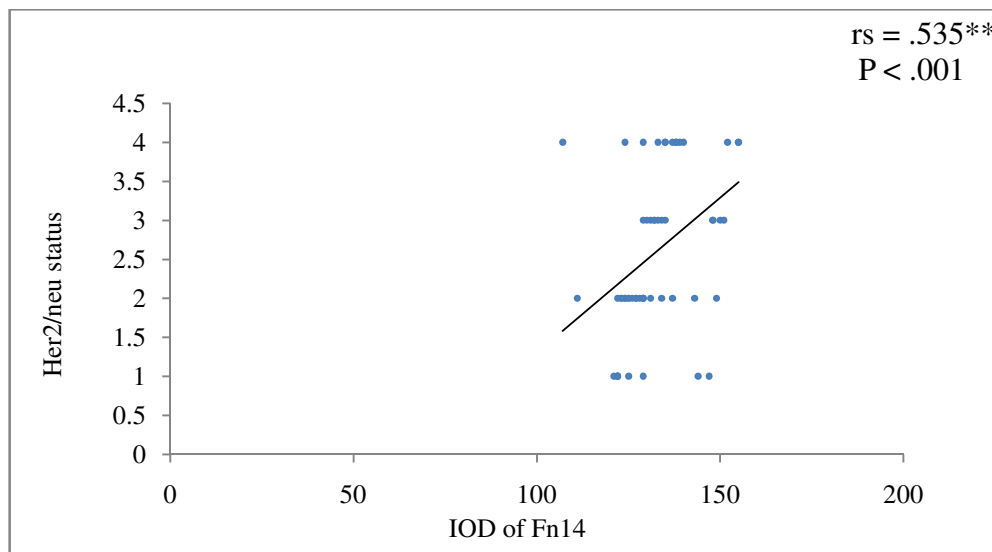


Figure-10
Correlation between IOD of Fn14 and HER2/neu status of breast cancer cases

Fibroblast growth factor-inducible 14-kDa protein (Fn14) is the cell surface receptor for the cytokine TNF-like weak (TWEAK) inducer of apoptosis¹⁵. Fn14 receptor is a regulator of breast cancer cell invasive capacity in multiple biological contexts because of its strong expression in many types of solid tumors and the intrinsic tumor cell killing capacity of the TWEAK-Fn14 pathway and thus a negative prognostic indicator and potential therapeutic target for breast cancer¹⁶.

The present study showed a statistical significant ($p < 0.05$) increase in the immunohistochemical expression of Fn14 in the malignant group versus normal and benign groups. This finding is in agreement with those reported by other studies^{12,15,17-19}.

In a previous survey examined 1,655 tumor samples across 22 solid tumor subtypes by immunohistochemistry, Fn14 expression was detected in the majority of tumor types, including pancreatic cancer (60%), non-small cell lung cancer (55%), bone metastases (54%) and liver metastases in colorectal cancer (50%)⁷.

The fact that Fn14 expression is increased in tumors as compared with normal tissue suggests that it may be a potential tumor antigen and therefore, on the basis of expression alone, a valuable therapeutic target¹¹.

The current results indicated that there was no statistical significant correlation between the immunohistochemical expression of Fn14 and clinical parameters such as age of the patient ($r = -.03, p = .82$) and size of the tumor ($r = .246, P = .058$). These findings are consistent with those reported by others¹².

A statistical significant correlation was noticed in the present study between Fn14's immunohistochemical expression and

LNM ($r = 0.28^*, P = 0.03$). This is in line with the results of others who reported that expression of Fn14 and its ligand TWEAK were both associated with metastasis and with four or more positive lymph nodes^{12,20}.

In the current study, Fn14's immunohistochemical expression has shown to be highly correlated with tumor histological grade ($r = 0.76^{**}, P < .001$). This finding is contrasted with the results of previous studies found no significant correlation between the expression of Fn14 and tumor histological grade¹², however the relation between the expression of Fn14 and higher tumor grade is going in accordance with the findings of other studies found significant correlation between the expression of Fn14 and more advanced tumor grade and poorer prognosis^{21,22}.

Fn14 expression and higher tumor grade and/or poor prognosis have been documented in brain¹⁰, esophageal⁹ prostate²³ gastric¹⁷, and bladder²⁴ cancers.

The represented results showed a statistical negative significant correlation between Fn14's immunohistochemical expression and both ER and PR ($r = -0.3, P = .031^*$), and a highly statistical significant correlation between its expression and HER2/neu ($r = .54^{**}, P < .001$). These findings are consistent with others who mentioned that Fn14 expression was higher in the Her2-positive/estrogen receptor-negative (HER2+/ER-) intrinsic subtype^{20,12} and although others reported no significant correlation between ER and PR levels and the expression of Fn14, they reported that Fn14 expression was positively related to HER2/neu expression¹².

Overexpression of HER2 which leads to constitutive kinase activation is associated with increased metastatic potential and poor prognosis²⁵. Previous immunohistochemical results revealed that HER2 and Fn14 were co-expressed in breast

tumors although their direct link is not yet clear⁹. Overexpression of HER2 can activate NF- κ B²⁶ and Fn14 is a NF- κ B-inducible gene¹⁰. Therefore, it is probably that NF- κ B activity may be one mechanism leading to activation of Fn14 gene expression in HER2 positive tumors patients.

Poor prognosis and short overall survival was reported in patients with positive Fn14 expression¹², this may clarify the significant association that was noticed in the present study between its expression and high tumor grade, LNM, ER negative and HER2 positive which are all signs of poor prognosis in the breast cancer.

Conclusion

In conclusion, the present study showed higher expression of Fn14 in IDC cases comparing to normal and benign cases, and this expression was closely correlated with high tumor grade, LNM and HER2/neu overexpression suggesting that Fn14 could be a valuable prognostic and therapeutic marker in IDC patients.

References

1. DeSantis C., Ma J., Bryan L., and Jemal A., Breast cancer statistics, 2013, *CA Cancer J. Clin.*, **64(1)**, 52-62 (2014)
2. Jemal A., Bray F., Center M.M., Ferlay J., Ward E. and Forman D., Global cancer statistics, *CA Cancer J. Clin.*, **61(2)**, 69-90 (2011)
3. Lehner J., Stötzer O.J., Fersching D., Nagel D. and Holdenrieder S., Circulating plasma DNA and DNA integrity in breast cancer patients undergoing neoadjuvant chemotherapy, *Clin. Chim. Acta.*, **425**, 206-11 (2013)
4. Shulman L.N., Willett W., Sievers A. and Knaul F.M., Breast cancer in developing countries: opportunities for improved survival, *J. Oncol.*, 595167 (2010)
5. Wiley S.R., Cassiano L., Lofton T., Davis-Smith T., Winkles J.A. and Lindner V.A. et al., A novel TNF receptor family member binds TWEAK and is implicated in angiogenesis, *Immunity*, **15(5)**, 837-46 (2001)
6. Winkles J.A., The TWEAK-Fn14 cytokine-receptor axis: discovery, biology and therapeutic targeting, *Nat. Rev. Drug Discov.*, **7(5)**, 411-25 (2008)
7. Culp P.A., Choi D., Zhang Y., Yin J., Seto P. and Ybarra S.E. et al., Antibodies to TWEAK receptor inhibits human tumor growth through dual mechanisms, *Clin. Cancer Res.*, **16(2)**, 497-508 (2010)
8. Han H., Bearss D.J., Browne L.W., Calaluce R., Nagle R.B. and Von Hoff D.D., Identification of differentially expressed genes in pancreatic cancer cells using cDNA microarray, *Cancer Res.*, **62(10)**, 2890-6 (2002)
9. Wang S., Zhan M., Yin J., Abraham J.M., Mori Y. and Sato F. et al. Transcriptional profiling suggests that Barrett's metaplasia is an early intermediate stage in esophageal adenocarcinogenesis, *Oncogene*, **25(23)**, 3346-56 (2006)
10. Tran N.L., McDonough W.S., Savitch B.A., Fortin S.P., Winkles J.A. and Symons M. et al. Increased fibroblast growth factor-inducible 14 expression levels promote glioma cell invasion via Rac1 and nuclear factor{ κ }B and correlate with poor patient outcome, *Cancer Res.*, **66(19)**, 9535-42 (2006)
11. Zhou H., John W., Walter N., Yagita H., Lawrence H. and Michael G. et al. Development and Characterization of a Potent Immunoconjugate Targeting the Fn14 Receptor on Solid Tumor Cells, *Mol. Cancer Ther.*, **10(7)**, 1276–88 (2011)
12. Wang J., Liu Y., Wei M.J., Mi X.Y. and Wang E.H., Clinical correlations and prognostic relevance of Fn14 expression in breast carcinoma, *Histol. Histopathol.*, **28(7)**, 859-64 (2013)
13. Matos L.L., Stabenow E., Tavares M.R., Ferraz A.R., Capelozzi V.L. and Pinhal M.A., Immunohistochemistry quantification by a digital computer-assisted method compared to semiquantitative analysis, *Clinics.*, **61(5)**, 417-24 (2006)
14. Ramos-Vara J.A. and Miller M.A., When tissue antigens and antibodies get along: revisiting the technical aspects of immunohistochemistry—the red, brown, and blue technique, *Vet Pathol.*, **51(1)**, 42-87 (2014)
15. Chao D.T., Su M., Tanlimco S., Sho M., Choi D. and Fox M. et al., Expression of TweakR in breast cancer and preclinical activity of enavatuzumab, a humanized anti-TweakRmAb, *J Cancer Res Clin Oncol.*, **139(2)**, 315-25 (2013)
16. Michaelson J.S., Amatucci A., Kelly R., Su L., Garber E., and Day E.S. et al., Development of an Fn14 agonistic antibody as an anti-tumor agent, *MAbs.*, **3(4)**, 362-75 (2011)
17. Kwon O.H., Kim J.H., Kim S.Y. and Kim Y.S., TWEAK/Fn14 signaling mediates gastric cancer cell resistance to 5-fluorouracil via NF- κ B activation, *Int J Oncol.*, **44(2)**, 583-90 (2014)
18. Gu L., Cao C., Zhu J., Ding C. and Xu H.B., Functional expression of TWEAK and the receptor Fn14 in human malignant ovarian tumors: possible implication for ovarian tumor intervention, *P LoS One.*, **8(3)**, e57436 (2013)
19. Asrani K., Keri R.A., Galisteo R., Brown S.A., Morgan S.J. and Ghosh A. et al., The HER2- and heregulin β 1 (HRG)-inducible TNFR superfamily member Fn14 promotes HRG-driven breast cancer cell migration, invasion, and MMP9 expression, *Mol Cancer*

- Res., **11(4)**, 393-404 (2013)
20. Willis A.L., Tran N.L., Chatigny J.M., Charlton N., Vu H. and Brown S.A. et al., The fibroblast growth factor-inducible 14 receptor is highly expressed in HER2-positive breast tumors and regulates breast cancer cell invasive capacity, *Mol Cancer Res.*, **6(5)**, 725-34 (2008)
21. Whitsett T.G., Mathews I.T., Cardone M.H., Lena R.J., Pierceall W.E. and Bittner M. et al. Mcl-1 mediates TWEAK/Fn14-induced non-small cell lung cancer survival and therapeutic response, *Mol Cancer Res.*, **12(4)**, 550-9 (2014)
22. Li N., Hu W.J., Shi J., Xue J., Guo W.X. and Zhang Y. et al., Roles of fibroblast growth factor-inducible 14 in hepatocellular carcinoma, *Asian Pac J Cancer Prev.*, **14(6)**, 3509-14 (2013)
23. Huang M., Narita S., Tsuchiya N., Ma Z., Numakura K. and Obara T. et al., Overexpression of Fn14 promotes androgen-independent prostate cancer progression through MMP-9 and correlates with poor treatment outcome, *Carcinogenesis.*, **32(11)**, 1589-96 (2011)
24. Als A.B., Dyrskjøt L., von der Maase H., Koed K., Mansilla F. and Toldbod H.E. et al., Emmprin and survivin predict response and survival following cisplatin-containing chemotherapy in patients with advanced bladder, *cancer. Clin Cancer Res.*, **13(15 Pt 1)**, 4407-14 (2007)
25. Hsieh A.C. and Moasser M.M., Targeting HER proteins in cancer therapy and the role of the non-target HER3, *Br J Cancer*, **97(4)**, 453-7 (2007)
26. Biswas D.K. and Iglehart J.D., Linkage between EGFR family receptors and nuclear factor kappaB (NF-kappaB) signaling in breast cancer, *J Cell Physiol.*, **209(3)**, 645-52 (2006)