

## Schilbach-Rott Syndrome and its management

Nandhagopal Vijayaraghavan<sup>1</sup>, Chittoria Ravi Kumar, Mohapatra D.P., Friji MT, Shivakumar Dinesh Kumar and Asokan Arjun

Department of Plastic Surgery, JIPMER, Pondicherry, INDIA

Available online at: [www.isca.in](http://www.isca.in), [www.isca.me](http://www.isca.me)

Received 10<sup>th</sup> October 2014, revised 12<sup>th</sup> November 2014, accepted 17<sup>th</sup> December 2014

### Abstract

*Schilbach-Rott Syndrome is a rare syndrome characterised by bycleft palate, ocular hypotelorism, hypospadias in males, blepharophimosis, upslant of palpebral fissures, and a tendency to cutaneous syndactyly of 3rd and 4th fingers as well as 2nd and 3rd toes. Here we are reporting the case with features resembling Schilbach-Rott syndrome and its management.*

**Keywords:** Schilback-Rott syndrome, Cleft palate.

### Introduction

Clefts of the orofacial region are one of the commonest birth defects. Most of these anomalies are non syndromic. But many cleft orofacial clefts are associated with other anomalies<sup>1</sup>. One of the lesser reported syndrome is the Schilbach–Rott syndrome. This syndrome was described by Schilbach and Rott in the year 1988<sup>2</sup>. Typically the characteristic features are ocular hypotelorism, cleft palate, hypospadias in males, blepharophimosis, upslant of palpebral fissures, and a tendency to cutaneous syndactyly of 3rd and 4th fingers as well as 2nd and 3rd toes. We are reporting a case with features resembling Schilbach-Rott syndrome and its management. On literature search in internet we found that only 18 cases have been reported to date with no case reported from INDIA of Schilback-Rott syndrome or features resembling this syndrome.

### Case Summary

The case reported is a 1 year old male child from a spontaneous pregnancy, born to non-consanguineous parents of Indian origin. The father was 32 years and mother 28 years old when the child was born. Delivery was spontaneous vaginal at 37 weeks. His birth weight was 2,400g. On examination child had dysmorphicfacies with ocular hypotelorism, prominent epicanthal folds, upward slant of palpebral fissure, low set ears with angulation and crumpling, cleft of palate, distal penile hypospadias with chordee and constriction band of the extremities. Ultrasound of the abdomen and cranium revealed no anomalies. ECHO was normal. Thyroid function tests revealed no anomalies. Karyotyping was 46XY. All the above features conformed to the findings of Schilbach-Rott syndrome figure-1 to 6. The management was planned to go for staged correction of all deformities. In the first stage cleft palate was repaired by intravelarveloplasty technique. Post-operative period was uneventful. Future plan is correction of hypospadias and constriction ring syndrome followed by correction of ear and eye anomalies in stages.

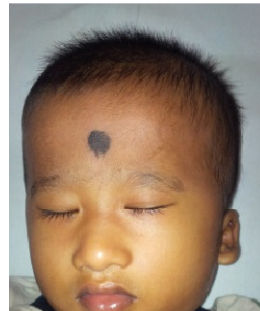

Figure-1

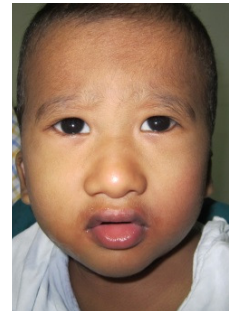


Figure-2

Figure-1,2

Showing hypotelorism, upward slanting palpebral fissure and low set crumpled ears

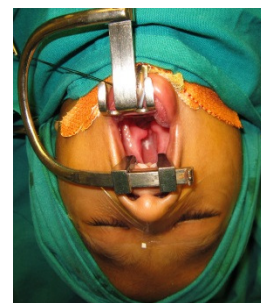

Figure-3

Cleft Palate pre-op

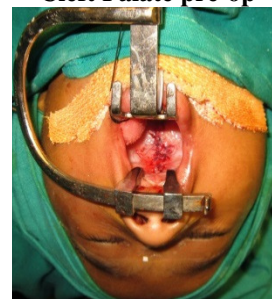
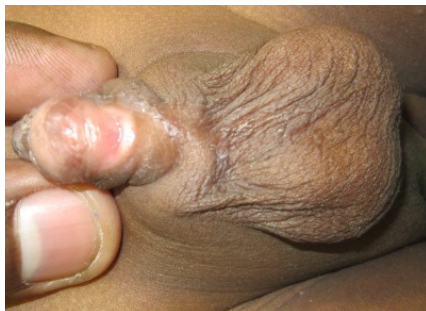
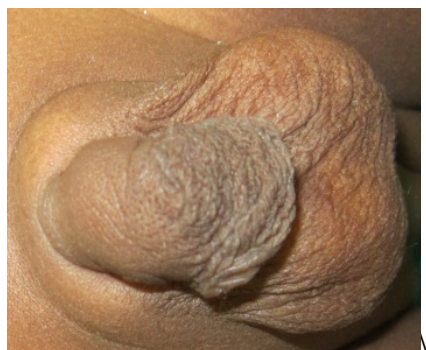Figure-4

Cleft Plate post-op



**Figure-5**  
**Penile hypospadias**



**Figure-6**  
**Dorsal hooded prepuce**

**Discussion:** Schilbach and Rott described a syndrome comprising ocular hypotelorism, epicanthic folds, upslanting palpebral fissures, blepharophimosis, and submucosal cleft palate in a mother and her three children. Both sons had hypospadias to varying degrees. Minor anomalies included mild cutaneous syndactyly of the third and fourth fingers and second and third toes. The children had normal heights and normal intellectual development. The original family described by Schilbach and Rott consisted of 10 individuals in five generations with syndromal hypospadias<sup>2</sup>. The aetiology is uncertain at present. The mode of inheritance is autosomal dominant. The other reports of this syndrome include Mexican father and son with Schilbach-Rott syndrome reported by Becerra-Solano, 4-year-old Brazilian girl reported by De Carvalho et al, Jewish family of Turkish-Libyan descent in which a father and his 2 offspring, a boy and a girl had features most reminiscent of Schilbach-Rott syndrome reported by Shkalim et al<sup>3-5</sup>. Two cases reported by Joss et al with cleft palate, hypospadias and facial appearance closely resemble Schilbach Rott syndrome<sup>6</sup>.

Our case had most features described by Schilbach and Rott. No family history of similar features could be obtained. After thorough examination and work up treatment plan was formulated taking into consideration all the anomalies. Due to functional significance palatal repair was done first. Post-operative speech therapy has been started by the speech and language pathologist. The further plans are repair of

hypospadias, extremity constriction ring correction followed by the ear and eye anomalies correction.

## Conclusion

Though Schilbach-Rott Syndrome is rare one should keep possibility in mind and look for features fitting or resembling this syndrome. In view of multiple congenital anomalies, staged reconstruction is desirable.

## Acknowledgement

All the Authors hereby disclose that there is no financial or any other conflict of interest.

## References

1. Venkatesh R., Syndromes and anomalies associated with cleft, *Indian J Plast Surg.*, **42(Suppl)**, S51-S55 (2009)
2. Schilbach U, Rott H.D., Neri G. and Reynolds JF., Ocular hypotelorism, submucosal cleft palate, and hypospadias: A new autosomal dominant syndrome, *Am. J. Med. Genet.*, **31**, 863-870 (1988)
3. Becerra-Solano L.E., Casillas-Avila M.P., Diaz-Rodriguez M., Nastasi-Catanese J.A., Toscano-Flores J.J. and Ramirez-Duenas M.L, Schilbach-Rott syndrome in a third family: further delineation of an autosomal dominant trait, *Genet. Counsel.*, **18**, 317-323 (2007)
4. De Carvalho D.R., Rossi N.F., Schellini S., Moretti-Ferreira D. and Richieri-Costa A., Schilbach-Rottble pharo facioskeletal syndrome in a Brazilian patient, *Am. J. Med. Genet.*, **146A**, 2134-2137 (2008)
5. Shkalim V., Baris H.N., Gal G., Gleiss R., Calderon S., Wessels M., Maat-Kievit A., Menten B., De Baere E., Hennekam R.C.M., Schirmacher A., Bale S., Shohat M. and Willems P.J., Autosomal dominant syndrome of mental retardation, hypotelorism, and cleft palate resembling Schilbach-Rott syndrome, *Am. J. Med. Genet.*, **149A**, 2700-2705 (2009)
6. Joss S.K., Paterson W., Donaldson M.D.C. and Tolmie J.L., Cleft palate, hypotelorism and hypospadias : Schilbach-Rott syndrome, *Am. J. Med. Genet.*, **113**, 105-107 (2002)