



## Toxicological Studies of Herbal Anti-Tumor Extract (*Uvaria Chamae*) in Monosodium Glutamate and Tamoxifen Treated Sprague-Dawley Rat

Tola Monday<sup>\*1,4</sup>, Ojokuku S.A<sup>2,4</sup>, Ogunyemi I.O.<sup>3,4</sup> and Odesanmi O.S.<sup>4</sup>

<sup>1</sup>Public Health Division, Nigerian Institute of Medical Research, Lagos, NIGERIA

<sup>2</sup>Department of Chemical Sciences, Yaba College of Technology, Lagos, NIGERIA

<sup>3</sup>National Agency for Food and Drug, Administration and Control, Ilorin, NIGERIA

<sup>4</sup>Department of Biochemistry, College of Medicine, University of Lagos, Lagos, NIGERIA

Available online at: [www.isca.in](http://www.isca.in), [www.isca.me](http://www.isca.me)

Received 10<sup>th</sup> May 2015, revised 25<sup>th</sup> May 2015, accepted 7<sup>th</sup> June 2015

### Abstract

Tumor cases are being linked to diet, lack of physical activity and overweight with Monosodium glutamate (MSG) and Tamoxifen (TAM) playing some roles. 45 female rats, weighing between 80g – 120g were divided into 3 main groups. 20 of the rats received MSG of 150mg/kg body weight, another 20 rats received TAM of 20mg/kg body weight and the remaining 5 rats were the control group. This was done for 30 days after which the rats were divided into 4 – subgroups and were treated for 21 days with ethanolic extract of *Uvaria Chamae*. They were then sacrificed, blood samples were collected into plain bottles and organs were harvested into universal bottle (fixed in 10% formal saline) for histopathology. It was observed that the amount of antibodies bound by the tumor markers was very significant in the MSG and TAM controls compared to the normal control (no tumor inducer rat). Administration of *Uvaria Chamae* extract was observed to cause very significant reduction in values of CA 15-3, CA-125 and CEA in both MSG and TAM groups compared to the untreated control. From the histopathology results, necrosis was observed in both treated and untreated groups of MSG and TAM but was not observed in the micrograph of the normal control. This study shows increase in the tumor markers values after induction with MSG and TAM, but *Uvaria Chamae* extract significantly reduced all values of the cancer tumor markers. The micrograph result showed damages done to the liver (by MSG and TAM), and this could not be corrected with *Uvaria Chamae* extract.

**Keywords:** Monosodium glutamate, *Uvaria Chamae*, Tamoxifen, tumor markers, necrosis.

### Introduction

A new report from the World Cancer Research Fund has indicated that 12 million new cases of cancer are diagnosed every year. According to this data released on September 9<sup>th</sup>, 2011, the rate has increased by a fifth under a decade with 2.8 million cases linked to diet, lack of physical activity and being overweight<sup>1</sup>.

The majority of primary breast tumours are oestrogen-dependent, and tamoxifen is the most commonly used antioestrogen therapy today. Tamoxifen is a selective estrogen receptor modulator (SERM) that is widely used in the treatment of patients with breast cancer and for chemoprophylaxis in high risk women. Tamoxifen results in a spectrum of abnormalities involving the genital tract, the most significant being an increased incidence of endometrial cancer and uterine sarcoma. Numerous animal models of breast cancer have previously demonstrated a proangiogenic effect of oestrogen and an antiangiogenic effect of tamoxifen *in vivo*<sup>2-8</sup>.

Monosodium glutamate (MSG) is the sodium salt of the non-essential amino acid, glutamic acid. Glutamic acid is one of the most abundant amino acids found in nature and exists both as

free glutamate and bound with other amino acids into protein. Glutamate is thus found in a wide variety of foods, and in its free form, where it has been shown to have a flavour enhancing effect, is also present in relatively high concentrations in some foods such as tomatoes, mushrooms, peas and certain cheeses. As a result of its flavour enhancing effects, glutamate is often deliberately added to foods – either as the purified monosodium salt (MSG) or as a component of a mix of amino acids and small peptides resulting from the acid or enzymatic hydrolysis of proteins.

Medicinal plants still remain the basis for development of modern drugs and medicinal plants have been used for years in daily life to treat diseases all over the world<sup>9</sup>. *Uvaria Chamae* is a plant commonly used to cure diseases and heal injuries. *Uvaria Chamae* is a plant with both medicinal and nutritional values. It has been reported that extracts of *Uvaria Chamae* have mutagenic effects. The drug benzyl benzoate used in antifungal preparations has a mutagenic compound, chamuvaritin, a benzyl dihydrochalcone that was isolated from *Uvaria Chamae*<sup>10</sup>. The root bark is used for respiratory catarrh and the root extract is used in phytomedicine for the treatment of piles, menorrhagia, epistaxis, haematuria and haemalysia<sup>11,12</sup>. A root infusion is used to cure abdominal pains. The juice from

the roots, stems or leaves is commonly applied to wounds and sores<sup>12</sup>. The antifungal and antibacterial inhibitory properties of the plant have been reported<sup>13</sup>. In folk medicine, extracts of the roots, barks and leaves are used to treat gastroenteritis, vomiting, diarrhea, dysentery, wounds, sore throats, inflamed gums and a number of other ailments<sup>14</sup>.

Toxicity, on the other hand, is complex with many influencing factors; dosage is the most important. Toxicity can result from adverse cellular, biochemical, or macromolecular changes. Examples are cell replacement, such as fibrosis, damage to an enzyme system, disruption of protein synthesis, production of reactive chemicals in cells and DNA damage.

There are many factors that can influence toxicity and this toxicity is triggered by some parameters. The toxicity of a substance depends on form and innate chemical activity, dosage, especially dose-time relationship, exposure route, age, sex, ability to be absorbed, metabolism, distribution within the body, excretion and presence of other chemicals.

The aim of this research is to study the toxicity of the ethanolic extract of *Uvaria Chamae* on tumour or tumour prone cells induced by the oral administration of Monosodium Glutamate and Tamoxifen in Sprague-Dawley rats and to evaluate the ameliorating effects of ethanolic extract of *Uvaria Chamae* through histopathological studies and cancer tumour markers.

## Material and Methods

**Collection of Plant Samples:** About 2kg of *Uvaria Chamae* root (locally called 'eruju') were bought from Mushin market, Mushin Local Government area of Lagos State, Nigeria. The sample was authenticated by Prof. J.O Olowokudejo of Botany Department, University of Lagos, and sample of the specimen

was kept in the herbarium.

**Animals and management:** A total of 45 female rats, 16-18 weeks old and weighing between 80g – 120g were obtained from the animal laboratory centre, College of Medicine, University of Lagos, Idi-araba. The rats were acclimatized for one month. The acclimatisation was needed so as to give the rats enough room to adjust to their new environment. The rats were divided into groups as in figure-1.

**Preparation of Ethanolic Plant Extract:** The plant's root sample was chopped into small pieces and air-dried for 2 weeks. The dried samples were then grounded into a uniform powder using a Thomas Wiley mill machine (Model Ed-5, USA). 2kg of this was weighed and then soaked in 70% ethanol for 72 hours after which it was sieved using muslin cloth. The plant extract was concentrated using the rotary evaporator and further evaporation was done in air-oven at 50°C. Steam evaporation using water bath set at 50°C was also carried out.

The ethanolic extract was then prepared into three different doses for administration, as follows: High dose (300mg/kg body weight), Middle dose (200mg/kg body weight) and Low dose (100mg/kg body weight). The average weight of the animals at the beginning of treatment was 100 ± 10.

**Administration of the tumour inducers:** After one month of acclimatization, the 20 rats in the tamoxifen group received 20mg/kg body weight dosage as specified on the drug leaflet and the 20 rats in monosodium glutamate group received 150mg/kg body weight. These inducers were administered orally. The normal controls were given distilled water. The administration was carried out for 30 days after which some of the animals were treated with the ethanolic plant extract.

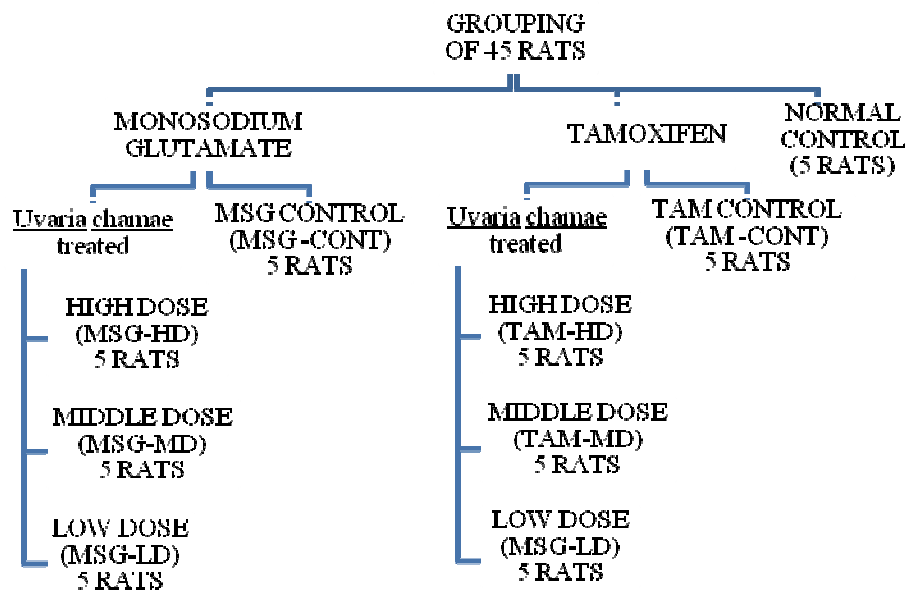


Figure-1  
 Experimental design

**Administration of Plant extract:** After 30 days of administration of the two inducers (MSG and Tamoxifen), the rats were divided into 4 – subgroups each as shown in Figure 1 above. The plant extract was also administered orally. The group controls were sacrificed before the administration of plant extract commenced. The administration was carried out for 21 days after which the animals were sacrificed

**Collection of blood samples:** After 21 days of the administration of the plant extract, the rats were fasted overnight. The following morning, the rats were weighed and collection of blood sample was done through ocular puncture i.e. using Na-Heparinized haematocrit tubes inserted through the optical sinus and collected into both EDTA bottles and plain bottles.

The rats were later sacrificed using cervical dislocation, organs were harvested weighed and stored in 10% formal saline for histopathological analysis. The organs harvested included the brain, liver, ovaries, kidneys and uterus.

Preparation of formal saline was done by adding 10mls of 100% stock of formalin to distilled water and making it up to 100mls with distilled water.

**Histopathological Analysis:** The organs for histopathology were collected into universal bottles, already containing 10% formalin (a fixative) and well labeled. The organs were dehydrated in graded alcohol, cleared with xylene, and embedded in paraffin. The resulting blocks were exhaustively sectioned. The tissues were cut into sections ≈ 3 microns, using microtome. The sections were randomized and selected sections were mounted and stained in haematoxyline and eosin. It was then cleared in xylene and the prepared slides were then sent for micrography and interpretation.

**Statistical Analysis:** Data were analyzed by comparing values from both the positive and negative control and also values from different treatment groups with values from untreated control (negative control). SPSS software package version 20 was used. Results were expressed as Mean ± Standard deviation. The significant difference among values was analyzed using analysis of variance (One-way ANOVA) at P≤0.05.

## Results and Discussion

It is observed from the result on table-1, that the amount of antibodies bound to by the tumour markers is very significant in the MSG and TAM controls as compared to the normal controls.

Figure-2 shows that there is a very significant reduction in values of CA 15-3 as the animals were treated with ethanolic extract of *Uvaria Chamae* as compared to the untreated controls in both MSG and TAM rats.

The result on figure-3 indicates a significant reduction in the values of CA-125 of animals given ethanolic extract of *Uvaria Chamae* (both high and middle doses) as compared to untreated control while no significant change is observed between the untreated control and low dose for MSG and but no significant drug effect was seen for TAM group.

CA15-3 levels are most useful in following the course of treatment in woman diagnosed with breast cancer, especially advanced breast cancer. Cancers of the ovary, lung, and prostate may also raise CA 15-3 levels. Elevated levels of CA 15-3 may be associated with non-cancerous conditions, such as benign breast or ovarian disease, endometriosis, pelvic inflammatory disease, and hepatitis. Pregnancy and lactation can also raise CA 15-3 levels.

From the results on CA15-3, it was showed that the inducer caused an increased value but *Uvaria Chamae* had a remedying effect thereby lowering the increased values.

CA-125 is best known as a marker for ovarian cancer, but it may also be elevated in other malignant cancers, including those originating in the endometrium, fallopian tubes, lungs, breast and gastrointestinal tract, CA-125 may also be elevated in a number of relatively benign conditions, such as endometriosis, several diseases of the ovary, and pregnancy. CA-125 is clinically approved for following the response to treatment and predicting prognosis after treatment.

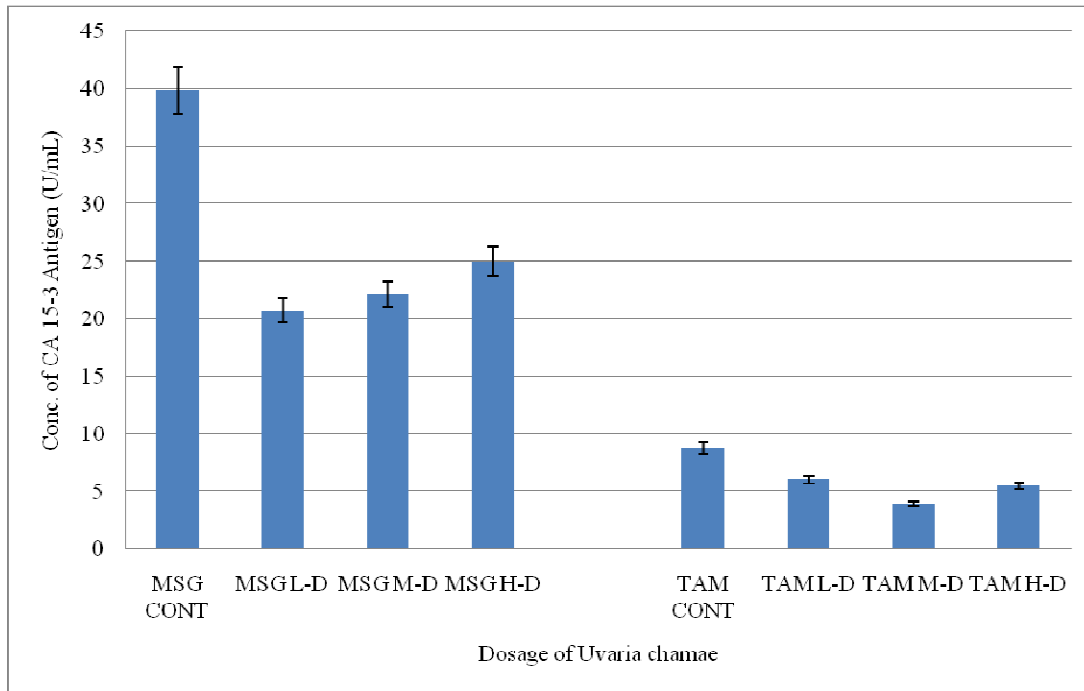
As observed, CA 15-3, CA-125 showed the same trend and that goes further to show the anticancer properties of the plant extract.

Table-1

Comparison of the levels of cancer tumour markers of normal controls and tumour inducers (MSG and TAM) controls

Groups	Doses (mg/kgBW)	Tumour Markers		
		CA 15-3(U/mL)	CA-125(U/mL)	CEA(U/mL)
Normal Controls	Nil	4.40 ± 0.64	3.22 ± 0.78	2.44 ± 0.80
MSG Controls	150mg/kgBW	39.88 ± 7.97**	15.00 ± 0.80**	4.66 ± 0.80**
TAM Control	20mg/kgBW	8.78 ± 0.38**	44.36 ± 10.13**	4.94 ± 0.98**

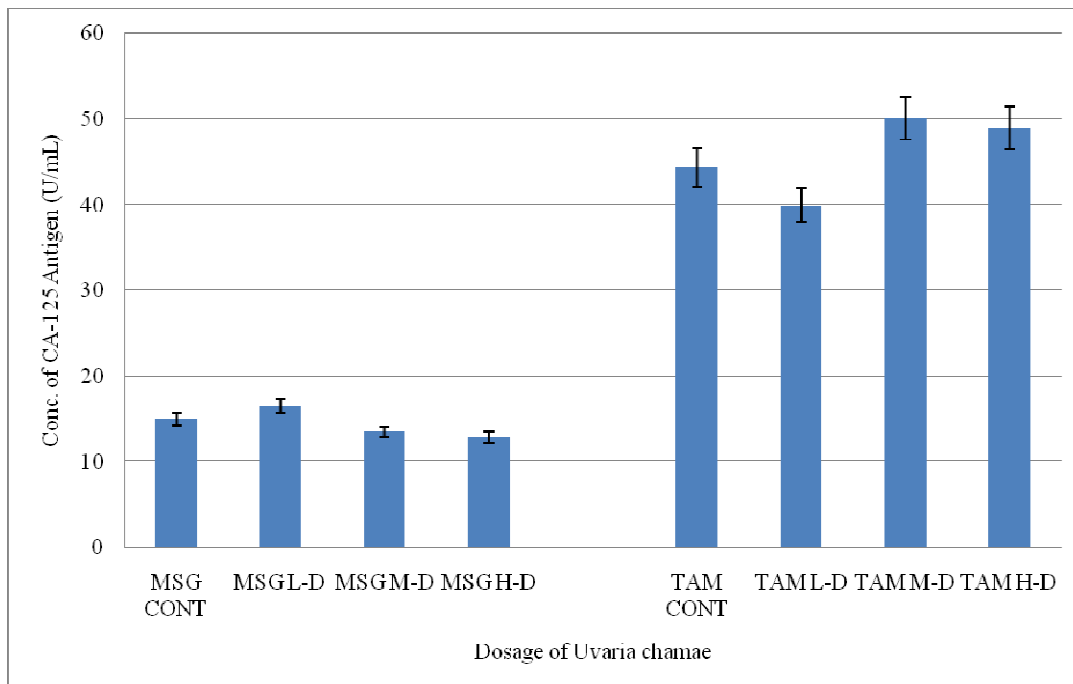
Values represent Mean ± S.D of 5 determinants. \*P≤0.05 – significant difference compared to control. \*\*P≤0.01 – very significant difference compared to control.



Values represent Mean  $\pm$  S.D of 5 determinants: \* $P \leq 0.05$  – significant difference compared to control.  
 \*\* $P \leq 0.01$  – very significant difference compared to control.

**Figure-2**

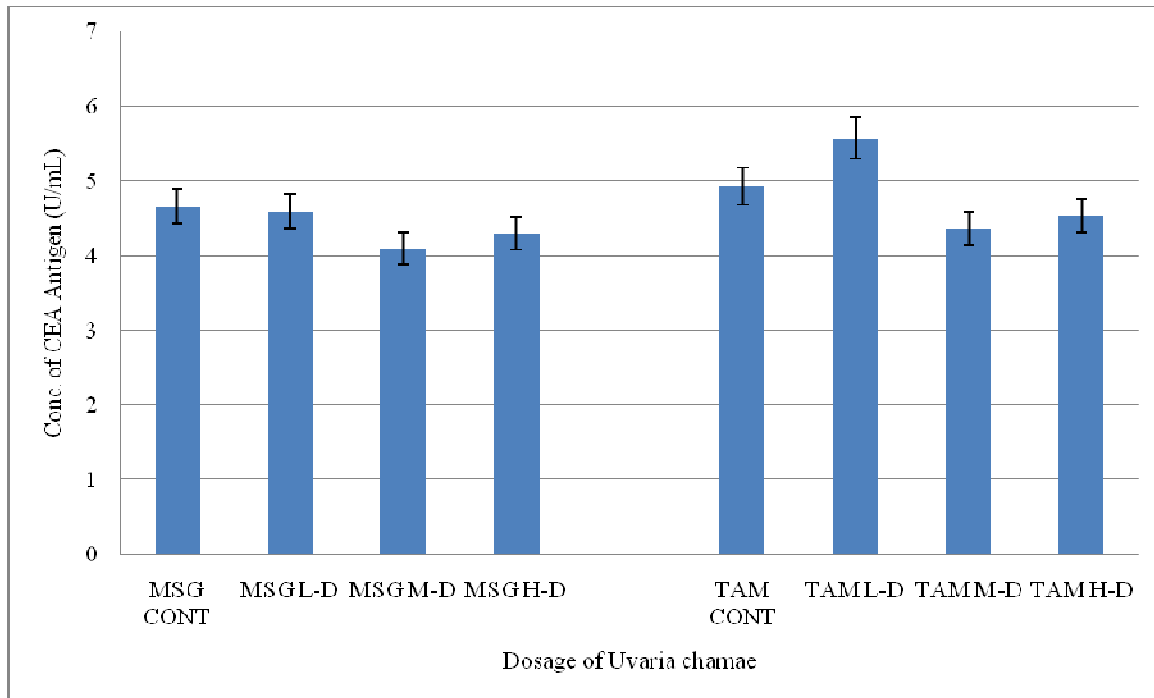
**Effect of oral administration of varied doses of *Uvaria Chamae* on CA15-3 with MSG and TAM induced toxicity in Sprague-Dawley rats**



Values represent Mean  $\pm$  S.D of 5 determinants. \* $P \leq 0.05$  – significant difference compared to control.  
 \*\* $P \leq 0.01$  – very significant difference compared to control.

**Figure-3**

**Effect of oral administration of varied doses of *Uvaria Chamae* on CA-125 with MSG and TAM induced toxicity in Sprague-Dawley rats**



Values represent Mean  $\pm$  S.D of 5 determinants. \* $P \leq 0.05$  – significant difference compared to control.  
 \*\* $P \leq 0.01$  – very significant difference compared to control.

**Figure-4**

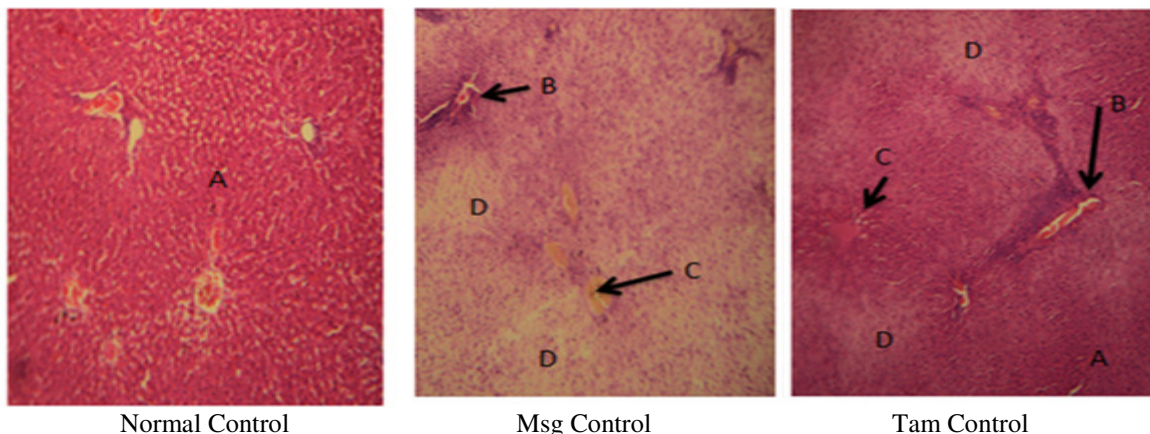
**Effect of oral administration of varied doses of Uvaria Chamae on CEA with MSG and TAM induced toxicity in Sprague-Dawleyrats**

The result on figure-4 shows a significant reduction in the values of CEA of animals given ethanolic extract of *Uvaria Chamae* (both high and middle doses) as compared to the untreated control while no significant change is observed between the untreated control and low dose for both MSG and TAM.

Carcinoembryonic antigen (CEA) is not usually present in the blood of healthy adult. CEA is considered a tumor marker. The

most frequent cancer causing an increased CEA is cancer of the colon and rectum. Others include cancers of the lung, pancreas, stomach, breast and some types of thyroid and ovarian cancers.

This goes to show the reason for the low values obtained since serum from the animal model was used. With the low values, significant reduction, towards normal control, was still noticed in some groups of animal, especially those given middle and high doses of the plant extract.



Normal Control

Msg Control

Tam Control

Legend: A = Normal Hepatocyte, B = Portal Tracts, C = Central Vains, D = Necrotic Hepatocyte, (Magnification = \*100)

**Figure-5**

**Effect of oral administration of monosodium glutamate and tamoxifen on the histology of the liver as compared to normal control**

From the micrograph result on figure-5, the normal control liver was observed to be normal, but Patchy hepatocyte necrosis was observed from the micrograph of Monosodium glutamate untreated animals and Focal areas or hepatocyte necrosis was observed from the micrograph of tamoxifen untreated animals.

Figure-6 shows that extensive areas of hepatocyte necrosis was observed from the micrograph results of *Uvaria Chamae* (low dose) and *Uvaria Chamae* (middle dose) treated animals in the MSG group, while extensive and widespread hepatocyte degeneration and necrosis with acute congestion was observed from the micrograph result of *Uvaria Chamae*(high dose) treated animals in the MSG group.

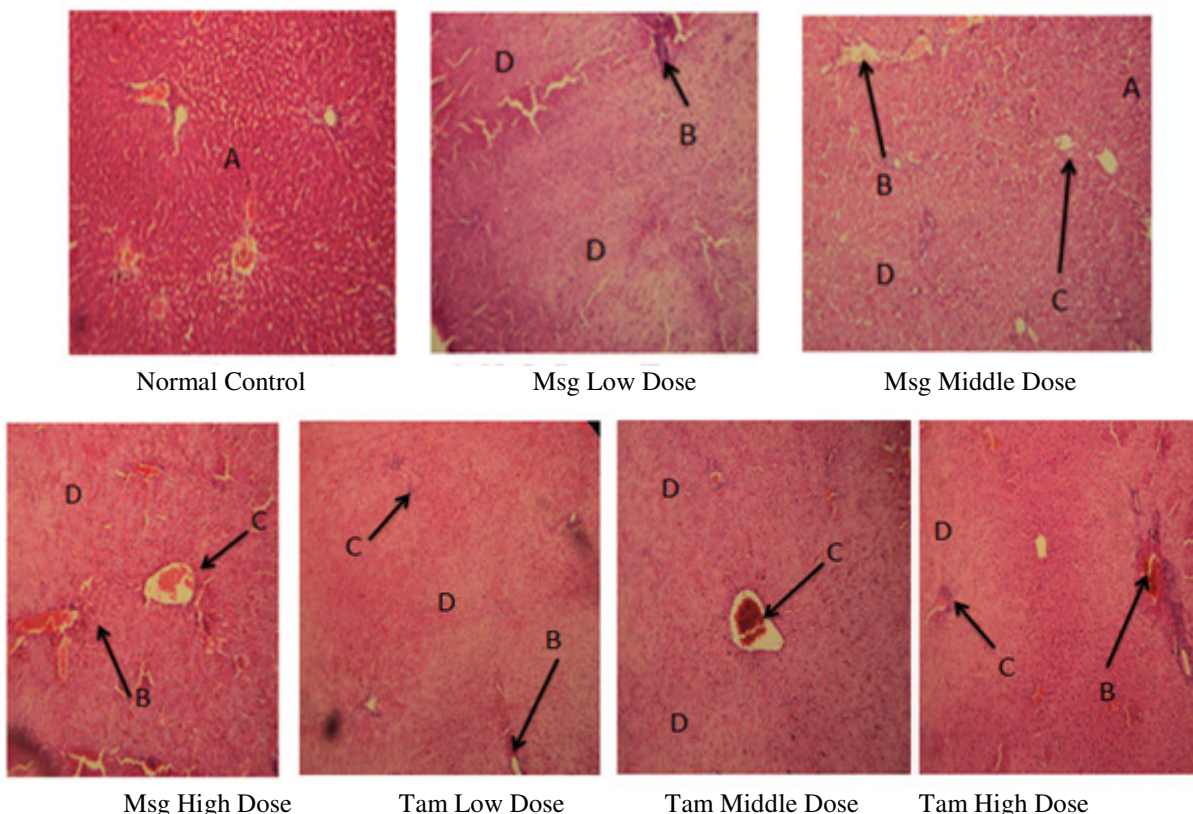
Figure-6 also shows that the micrograph results of *Uvaria Chamae* (low dose) treated animals in the TAM group was normal, while focal hepatocyte degeneration and acute congestion was observed in the micrograph results of *Uvaria Chamae* (middle dose) and *Uvaria Chamae* (high dose) treated animals in the TAM group.

The liver is an organ of detoxification, metabolizing drugs and other foreign substance taking by organisms. In cases of hepatic diseases or disorder, this basic function of the liver is lost<sup>15</sup>.

Prolonged administration of MSG and TAM resulted in degenerative and atrophic change observed in the lung. The actual mechanism by which monosodium glutamate induced cellular degeneration observed in this study needs further investigation. The necrosis observed is probably due to the high concentration of the tumor inducers on the liver. Necrosis is due to the fact that the inducers are preventing the affected cells from getting access to oxygen. This leads to cell death. These dead cells tend not to be pigmented as observed from the micrograph above. Pathological or accidental cell death is regarded as necrosis and could result from extrinsic insult to the cell as osmotic, thermal, toxic and traumatic effects<sup>16</sup>.

The process of cellular necrosis involves disruption of membranes, as well as structural and functional integrity. This cellular necrosis is due to an abrupt environmental perturbation and departure from the normal physiological conditions<sup>17</sup>. In cellular necrosis, the rate progression depends on the severity of the environmental perturbation. The greater the severity of the insults, the more rapid the progression of neuronal injury<sup>18</sup>.

It was observed from all the results obtained (from the micrograph results), that *Uvaria Chamae* could not regenerate the damaged tissues caused by the inducers. The principle holds true for toxicological insult to the brain and other organs.



Legend: A = Normal Hepatocyte, B = Portal Tracts, C = Central Vains, D = Necrotic Hepatocyte, (Magnification = \*100)

**Figure- 6**

**Effects of oral administration of varied doses of *Uvaria Chamae* on the histology of the liver of MSG and TAM induced rats**

## Conclusion

From all the result obtained above, it has been shown that even with the limited numbers of days of tumor induction, MSG (especially) and Tamoxifen could be a very good source of tumor induction as observed from the increased values of the cancer tumor markers as compared to the normal control groups.

*Uvaria Chamae* (especially the high and middle doses) from these studies has been shown to have a corrective effect by reducing all the tumor marker values (that is, reducing the tumor markers toward the normal control group). This goes to show that *Uvaria Chamae* is a good anti-tumor plant. It should also be noted that from the histology of the organs studied, *Uvaria Chamae* ethanolic extract does not have regenerative properties.

## References

1. World Cancer Research Fund, WCFR (www.wcfr.org), The Punch Newspaper, September 14<sup>th</sup>, (2011)
2. Haran E.F., Maretzek A.F., Goldberg I., Horowitz A. and Degani H., Tamoxifen Enhances Cell Death in Implanted MCF7 Breast Cancer by Inhibiting Endothelium Growth, *Cancer Res.*, **54**, 5511–5514 (1994)
3. Lindner D.J. and Borden E.C., Effects of tamoxifen and interferon-beta or the combination on tumor-induced angiogenesis, *Int J Cancer.*, **71**, 456–461 (1997)
4. Guo Y., Mazar A.P., Lebrun J.J. and Rabbani S.A., An Antiangiogenic Urokinase-derived Peptide Combined with Tamoxifen Decreases Tumor Growth and Metastasis in a Syngenic Model of Breast Cancer, *Cancer Res.*, **62**, 4678–4684(2002)
5. Dabrosin C., Margetts P.J. and Gauldie J., Estradiol Increases Extracellular Levels of Vascular Endothelial Growth Factor *In Vivo* in Murine Mammary Cancer, *Int J Cancer.*, **107**, 535–540 (2003a)
6. Dabrosin C., Palmer K., Muller W.J. and Gauldie J., Estradiol Promotes Growth and Angiogenesis in Polyoma Middle Transgenic Mouse Mammary Tumor Explants, *Breast Cancer Res Treat.*, **78**, 1–6 (2003b)
7. Garvin S. and Dabrosin C., Tamoxifen Inhibits Secretion of Vascular Endothelial Growth Factor in Breast Cancer *In Vivo*, *Cancer Res.*, **63**, 8742–8748 (2003)
8. Elkin M., Orgel A. and Kleinman H.K., An Angiogenic Switch in Breast Cancer Involves Estrogen and Soluble Vascular Endothelial Growth Factor Receptor 1, *J Natl Cancer Inst.*, **96**, 875–878 (2004)
9. Ates D.A. and Erdogru O.T., Antimicrobial Activities of Various Medicinal and Commercial Plant Extracts, *Turk, J. Biol.*, **27**, 157-162(2003)
10. Okogun J.I., Drug Production Efforts in Nigeria, Medicinal Chemistry Research and Missing Link, Being a Text of a Lecture given to the Nigeria Acad Sci., 29-52 (1985)
11. Oliver B., Medicinal Plants in Tropical West Africa, Cambridge, 123-125 (1986)
12. Irvin F.R., Woody Plants of Ghana with Special Reference to their Uses, Oxford University Press, London, 19, 20, 695 (1961)
13. Okwu D.E. and Iroabuchi F., Classification of *Uvaria Chamae*, *J.Chem Soc., Nigeria*, **29(2)**, 112-114 (2004)
14. Okwu D.E., Medicinal Properties of *Uvaria Chamae* Root, Stem and Leaves, *Med Aromat Plant Sci Biotechnol.*, **1(1)**, 90-96 (2007)
15. Bolarin D.M. and Bolarin A.T., Revision Note on Chemical Pathology, 1<sup>st</sup> Edn. Lantern Books, Lagos, 210-247, (2005)
16. Farber J.L., Chein K.R. and Mittnacht S., The Pathogenesis of Irreversible Cell Injury in Ischemia, *Am J. Pathol.*, **102**, 271-281 (1981)
17. Belluardo M., Mudo G. and Bindoni M., Effect of Early Destruction of the Mouse Arcute Nucleus by MSG on Age Dependent Natural Killer Activity, *Brain Res.*, **534**, 225-333 (1990)
18. Martins L.J., Deobler J.A., Shih T. and Anthony A., Cytophotometric Analysis of Thalamic Neuronal RNA in some Intoxicated Rats, *Life Sci.*, **35**, 1593-1600 (1984)