



Critical Evaluation and Contribution of Virtopsy to Solved Crime

Sharma Mahesh¹ and Singh Ranjeet Kumar²

¹Anglia Ruskin University, East Road, Cambridge, CB1 1PT, ENGLAND

²Sherlock Institute of Forensic Science India, Hudson Line, Delhi 110009, INDIA

Available online at: www.isca.in, www.isca.me

Received 24th December 2014, revised 12th January 2015, accepted 26th January 2015

Abstract

Radiology in autopsy and forensic investigations became well-known and regularly useful for documentation of fractures, injury patterns, foreign body and metallic remains localization if finger prints and DNA are not available, or if we are can't use other technique. Radiography is an addition of CT and MR. Because of this in forensic pathology, CT became suitable diagnostic tool because it's a very quick procedure and with less blood or without. Virtopsy is independent of investigator and because of quick results it is available at the time of autopsy to predict valuable information for investigator. Virtopsy generated records are two or three dimension, which can be renovated as long as after autopsy. Firstly, background of autopsy and virtopsy. It, will help how virtopsy continues developing & supports traditional autopsy. Secondly, different technique involved in virtopsy like, CT MRI, GOM – high-resolution surface scanner, Angiography – post-mortem heart-lung machine, Programmable biopsy –contamination-free sampling, ultrasound technology, Animations in Forensic Pathology. Thirdly, both technologies have their negative effect but beneficial aspects are many. That's why both techniques are very common in use of forensic purpose to support crime evidence. Then case study to make clear deference between both with suitable picture example. Then discussion will gives valuable information to investigator to make more evidences for court. Finally, conclusion and reference will give value of this writing.

Keywords: Computational, forensics, virtopsy, investigations, technique, animations, pathology, autopsy.

Introduction

Radiology in autopsy and forensic investigations became well-known and regularly useful for documentation of fractures, injury patterns, foreign body and metallic remains localization if finger prints and DNA are not available or we are can't use other technique. Radiography is an addition of CT and MR¹. Because of this in forensic pathology, CT became suitable diagnostic tool because it's very quick procedure and with less blood or without. Virtopsy is independent of investigator and because of quick results it is available at the time of autopsy to predict valuable information for investigator. Virtopsy generated records are two or three dimension, which can be renovate as long as after autopsy². Firstly this essay will give history background of autopsy and virtopsy. It, will help to understand how virtopsy is continues developing its applications to support traditional autopsy. Secondly, essay will describe different technique involved in virtopsy like, CT MRI, GOM – high-resolution surface scanner, Angiography – post-mortem heart-lung machine, Programmable biopsy –contamination-free sampling, ultrasound technology, Animations in Forensic Pathology. Thirdly, this essay will show some negative and positive points of autopsy and virtopsy because both technologies have their negative effect but beneficial aspects are many. That's why both techniques are very common in use forensic purpose to support crime evidence. Then this writing work shows one case study to make clear deference between autopsy and virtopsy with some suitable picture example. Then

discussion will shows how this technology gives valuable information to investigator to make more evidences for court. Finally, conclusion and reference will give value of this writing.

Virtopsy and Autopsy back ground Information's

Term autopsy is originally come from Greek words for "self" (autos) and "I will see" (opsomei) – "Tosee with one's own eyes". In a 6th century B.C. in India, Sushruta practiced autopsy from near the beginning lead the way of ayurveda (The Indian art of medicine). In the third century B.C. to build up knowledge of anatomy and disease, he describe autopsy. In 1761, Giovanni Batista describes and published nearly 700 autopsies done by him in his book "*The seats and cause of diseases investigate by anatomy*". For medical and clinical purpose Osler established autopsy in at the end of nineteenth century. Here student are trained to do autopsy. In 1960 to 1970, DeBakey and his team developed many techniques for autopsy and lead using cadaveric testing³. The autopsy was at the core of medical research, education and professional development until the 1960 doctors believed that, progress in medicine come due to contribution of autopsy. In addition autopsy plays various roles in modern medicine and its discovery, understating and characterization of pathological process⁴.

Forensic assessment concerned the visual inspection of injury pattern in addition to support forensic autopsy and histological inspection. Modern radiographic technique like CT and MRI are

able to produce three-dimension information of tissue damage^{5,6}. Basic of imaging autopsy (IA) is use high definition CT and/or MRI or we can say, imaging autopsy is an addition of computed tomography (CT) and magnetic resonance imaging (MRI). In 1977, Wullenweber et al. explain radiographic pattern of gunshot injuries with the help of new forensic application computer tomography (CT). Comparison study of autopsy and premortem CT is done by Flodmark et al. in 1980. After 10 years Kalender et al. build up three-dimensional digital radiographic imaging data. Major research work on virtopsy project was done by University of Bern in 1990³. Advantages are many to including imaging virtopsy resolve reason of date, sex classification in difficult case, detection of length and other parts, understanding of injuries respect to forensic aspect, three dimension (3D) renovations for angle of bullet direction recherché for medical history³. Currently imaging autopsy is being carried out after traditional autopsy to get supplementary information's of skeletal, muscular and the structure which is not observed during autopsy³.

Controversies: During study of imaging autopsy there are some arguments. First who need to be in charge for this kind of interpreting cases? Second, who will cover this cost? The cost of CT/MRI between \$550 to \$1000 without radiologist salary but it also depend how wide study and how many body parts imaged? Thirdly, inconsistency of terminology by different-different research groups for this technique like CATopsy, virtopsy, virtual autopsy or imaging autopsy in addition it can be referred computed tomographic imagining autopsy or magnetic resonance imaging autopsy³.

Different Virtopsy Technique

NIS (National Institute of Health – Washington) presents idea “all in one” later it is realized by Forensic Medicine of the University of Berne as an “all in one research area”. Aim of this idea to encourage virtopsy as a promising field with clear and controlled procedure. Virtopsy start from surface documentations carry on with CT scanning and fallowed with image-controlled sampling for histological, bacteriological and toxicological examination⁷.

CT – computed tomography for three-dimensional imaging: First CT image method was without analysis of human body but it permitted to view inside the body. To generate X-rays, CT and radiography use same procedure and get transverse image of body parts. After applying X-ray on body, these rays became attenuated by body tissue and receive by detector system behind the body. Specific numbers of rotations of X-rays produce an image, which are measurements of different angles to produce a pixel. First CT image took around 25 mints and gave image of brain. Morden 64-slice scanner is 192 times faster than single-slice spiral CT of 1990 and also achievements of results with high contrast better then single-slice helical⁷.

GOM – high-resolution surface scanner: Bern University of

Forensic Medicine use GOM TRITOP/ATOS to documentation of body surface, tools and vehicles. It is able to produce true 3D colour of surface of body and vehicles. It has high stability, accuracy, easy to use, flexible, and mobile. It can compose 3D data automatically. All objects size and complexities the system produce high accurate 3D coordination of millions of surface points⁷.

Angiography – post-mortem heart-lung machine: Intra-vascular and intra-articular display can be seen small as well as longer circulatory system. In some cases individual body organs or body regions can be analysis and vascular injury leakages and permitting quantification of stenosis. It can be controlled dynamically⁷. Angiography is limited for post-mortems and animal research but advantages are more, mainly micro scoping presentation of vines and arteries⁸.

Programmable biopsy –contamination-free sampling: Body fluids can be examined for toxicological purpose to diagnostic properties. This approach offer less manpower, decries examination time and use navigation and robotic technologies⁷.

Ultrasound Technology: t is easy to gain knowledge and utilize ultrasonographic technique. It is being used in many clinical circumstances in additions it is able to produce pictures of anatomical structures like cardiac evaluation, tumours, abscesses, vascular structures, solid organ assessment, and pregnancy, and more. Possible use of ultra sound in post-mortem may engage sonographic assessment of different organs, pleural effusions and pleural air, cardiac and pericardial abnormalities, hem peritoneum and skeletal injuries. In a few post-mortem reports have seen use of ultrasound and this technology may provide an additional use for modern imaging modalities in a difficult process of cause-of-death³.

Animations in Forensic Pathology: Animations can support to forensic pathologists to process complex evidence to communicate for juries in a clear-cut and easy mode. Animation consign to dynamic illustration, data from forensic crime scene can give considerable three-dimensional data visualization. “Animations can help forensic pathologists communicate complex medical evidence” This visual can also help to member of jury to give technical (biological or medicinal) complex information of case because they do not need to be expert for forensic aspect. Data from crime scene, realistic biological models of human body and modelled in a computer based on physic, can be digitalize and animated which can lead crime scene interaction. This computer based modelling of forensic data give many advantages but most important purpose is comparison between crime scene evidence and biological evidence from victim. In addition study of gunshot wound, car accidents, tire trace, match bite marks. It can also apply on biological hypotheses how injury has been happened⁹?

There is a good example of forensic animation from the virtopsy system. The given gun shoot images is designed with the help of

forensic CT scan data from crime scene and it is anatomically accurate computer created animation. There are also image of traffic accident, figure-1 first one show the position of victim and other shows his bone structure. Establishment of image have done with the help of victim evidence from crime scene⁹.

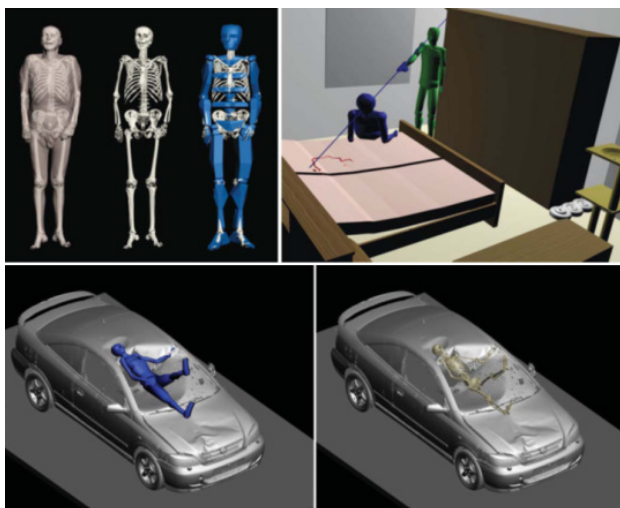


Figure-1

Show the position of victim and other shows his bone structure. Establishment of image have done with the help of victim evidence from crime scene⁹

Several gunshot wounds and internal harms on organs were examined at the time of autopsy and it was rebuild and describe with the help of three dimension animation by a pathologist see figure 2 as an evidence because he know the position of wound with respect to direction of organ damaged can give result on range and angle of firing. This figure-2 show all the angle of firing¹⁰.

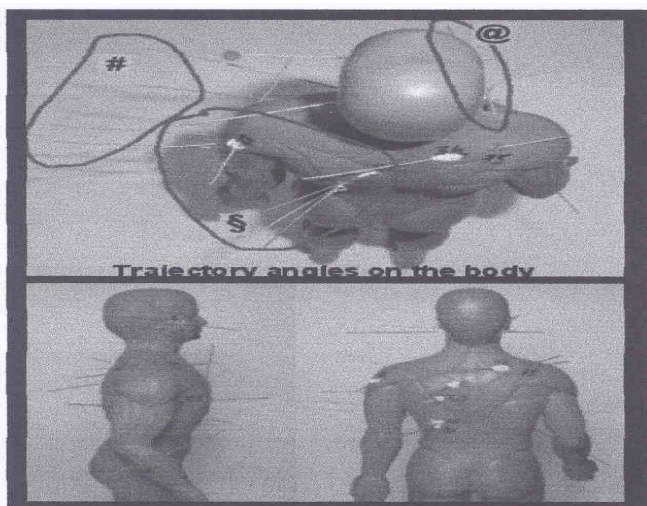


Figure-2

The alignment of the multiple gunshot wounds and injuries on the body consistent with three different gunshot attacks¹⁰

Animation models can describe skin, tissue and each layer of body in 3D view (Christos D K. and et al. (2006).

Disadvantages of animation, computer software does not contain any physical constraint based upon reality so wrong data or evidence information can easily sneak in animation⁹.

Photography: According to Keith, I. and Norah, R., In 1854 Maddox an English physician introduced dry plate photography for prison record. Then in 1864 first advocate Odelbrecht, apply photography for crime scene evidence and identification of criminals. After a forensic chemist Paul Jesrich in 1898, compare two bullets after taking photomicrographs¹¹. Photography, scaling, note taking and videography are four main tasks of documentations. At crime scene photography is first task of investigator because it not only provides exact image record of the crime scene but also show present physical evidence. This photo should be keep for record with all parameter like distance of camera and object, time, speed of shutter and more. Advantages of this digital image technology are many, like its easy, integration with digital data and chip¹².

Disadvantages of this digital image technique are few. According to the law enforcement community, digital image is the best as a supplementary technique but it can't replace completely the traditional technique. Image manipulation¹².

Advantages and Disadvantages

Why use advanced post-mortem imaging?: The digital data of imaging technique are switch and assess by remote commutation and it is raising future of "tele-forensics". Few mouse clicks can predict proficient judgement simply and quickly. Location and time is not an issue for physician to get view of experts internationally because allowances renewed of virtopsy⁷. There are many aspects to execute imaging autopsy. Like i. resolve cause of death; ii. sex detection in tricky forensic cases; iii. length of body and personal decedent characteristic recognition; iv. discover distinct foreign bodies – retained bullets, blades, etc.; v. detection of more possible injury and forensic renovation – three dimensional reconstructions, bullet tract identification; vi. education and clinical performance development process; and vii. explore – from medical to historical³. Non-destructive virtopsy is easy to acceptable by religious community. Non-destructive documentation virtopsy explain no information lose due to post-mortem revision. Virtopsy data are digital and it allows to reconstruct forensic documents so far away. Virtopsy supports to access histological, bacteriological and toxicological examination in cases of nuclear, bacteriological and chemical terrorism⁷. Advantages are many as including imaging virtopsy resolve reason of date, sex classification in difficult case, detection of length and other parts, understanding of injuries respect to forensic aspect, three dimension (3D) renovations for angle of bullet direction recherche for medical history³.

Limitations of Imaging Autopsy: There are some limitations of imaging autopsy. Firstly, radiographic autopsy technique can't become aware of all possible result for death. Then, sometimes critical finding may be missed during imaging autopsy analysis it is less chance to accrue this mistake in Morden radiology because of continues improvements. Imaging autopsy require more skills to give information's about circulatory and metabolic action to make it visualized. Then, bulk of imaging autopsy occurrence reports comes from trauma and forensic medicine and it is uncertain how CT and MRI technique can be supportive in post-mortem valuation in a general medical or surgical population. All of these points open the access for further research because while devastating traumatic injuries can be seen on virtual autopsy and also cause of death due to metabolic or disorders can lead most particular and responsive imaging technique. Also, study about intravascular and intrahepatic air need to be expounded for CT and MRI technique³.

Image resolutions of MRI are narrow and propose less accurate judgment, like autopsy can offer judgment on acute myocardial infection secondary to coronary artery thrombosis but MRI can give only information about ischaemic heart disease. Only image of MRI can't provide information of toxicity, microbiological testing. Autopsy can performed more than one time if needed but MRI is five times costly⁴. Imaging autopsy can be complicated if handling is not proper during transport, if body is covered in bag that's why it is important to handle body carefully during intra-hospital transport. Contribution of CT and MRI scanner became accessible to get absolute achievements to give imaging autopsy but it also became topic of debate by which this imaging autopsy should be compare. It seems to be in a future this imaging autopsy will be interpreted between pathologists, radiologist and patient's primary doctor³. MRI may give valuable information about expression of gas in intraparenchymal blood vessels of internal organs but in a case of 27 year old man, MRI scan couldn't disclose any intravascular air bubbles¹³.

Imaging Autopsy: Complementary To Traditional Autopsy: Patients relative don't want autopsy because of bad impartation of some negative media coverage like Alder Hospital and the British Royal Infirmary for research purpose gained plenty of negative media coverage about unauthorised retentions of human tissue and organs of deceased. Lack of information's can also lead public misinterpretation of autopsy and relatives always confuse to get precise information, so it is not easy to organized funeral for them and they can't appreciate with complicated procedure. It is hard to find exact cause of death without hurting dignity. Then suspicions misappropriate body handling, religious objectives and morality is common in virtopsy⁴. Less co-operation between clinicians and pathologist to describe post-mortem reports because of time and lack of direct interactions. In a given 43.4% cases clinicians only requested 6.2% of autopsy and many clinicians think it autopsy is outdated due to addition of radiological imaging technique,

which can give high quality wise and more accurate information's⁴. The Broderick statement and a combined statement between the Royal College of Physicians and the Royal College of Pathologists propose that, death certificate should be carry out by senior doctors because many doctors reports are lack of training and self-assurance consent of post mortem⁴. 81% cases autopsy gave more valuable diagnosis result when it performed with virtopsy. Because of pre-autopsy MRI technique traditional autopsy became more dynamic in a forensic autopsy practice and discovery of virtopsy⁴.

Case Study

Photogrammetric documentation was first action for external examination in case of 53 years old male swimmer stuck in bucket wheel of a steamboat. Radiological examination or virtopsy approaches was MSCT and MRI then traditional autopsy¹⁴. In a given figure-3 image (a) external inspection shows haemorrhages on skin at back side of body, which are diagonally tape like over the body and dislocation of arm. Image (b) is a MR image of body, which describe 8-10th thoracic vertebrae are placed to cutaneous and subcutaneous haemorrhages. This picture also shows s dislocation of right shoulder. Image of MSCT and MRI revealed a massive haematothorax in a left but smaller at right side. Picture (c) is an example of traditional autopsy, in this image subcutaneous haemorrhages indicate by thin arrow in addition the thick arrow shows soft tissue haematoma at left side¹⁴. Figure 4, Image (a) is MSCT, which is restructured three-dimension model of bones without sternum and ventral parts and Image (b) is an autopsy image. Both picture shows dislocation of arms. Then arrows in virtopsy image describe fractured in ribs and vertebrae because of this in autopsy image around the soft tissue of fractured vertebrae, para-vertebral extra-pleura haemorrhage¹⁴. Figure 5, Picture (a) is a MSCT which shows rupture of aorta and fracture of vertebrae same visual indication in picture (b) and also show with dotted line fluid in stomach¹⁴. Figure 6, Image a, b and c is followed by MSCT, MRI and autopsy. All picture shows complete rupture of aorta¹⁴. Figure 7 "(a) Fluid in the paranasal cavities in axial planes (b) 3D reconstruction of the structures with fluid-like signal intensity in MRI. Fluid in the stomach and duodenum marked with thick arrows, fluid in the trachea with dotted arrow. Furthermore, fluid part of haemorrhages around the fractured ribs is viewable (double arrow). (c) Emphysema aquosum in axial MSCT slide. Over inflation of the both lungs. The front edges of the lungs contact each other in the front of the heart (arrow). Note the mediastinal shift to the right side caused by haematothorax (HT). (d) Emphysema aquosum at autopsy. Both lungs are over inflated and expand out of the thorax cavities". Figure 8 During algological analysis Diatom *Cyclotella cyclopuncta* found in lung tissue as well as same found in water sample of lake¹⁴.

Discussions

According to Richard, CT produce X-rays from end and it

penetrate in to body and tissues then from other end it receive by detector finally predict an image of body to give valuable information to investigator⁷. Angiography also provides internal microscopic presentation of vines and arteries⁸. It can be done by Ultra sound. It gives us vascular structure of human body in addition it is able to produce pregnancy, solid organ assessments, tumours, and anatomy structure of human body³. If we talk about surface of body so GOM high resolution surface scanner is mobile, easy to use; it gives high stability and

accuracy result of body surface which is in 3D and colourful image⁷. Photography is helpful to give accurate crimes evidence of scene and also comparison between crime scenes to others evidence¹². But Gary said, animation help member of jury because its three dimension visual data⁹. which, can be inside of body like structure of artery sans veins or outside about three dimension gun shoot presentations. Over all we can say it's all this imaging techniques are very helpful to support to prove crime.

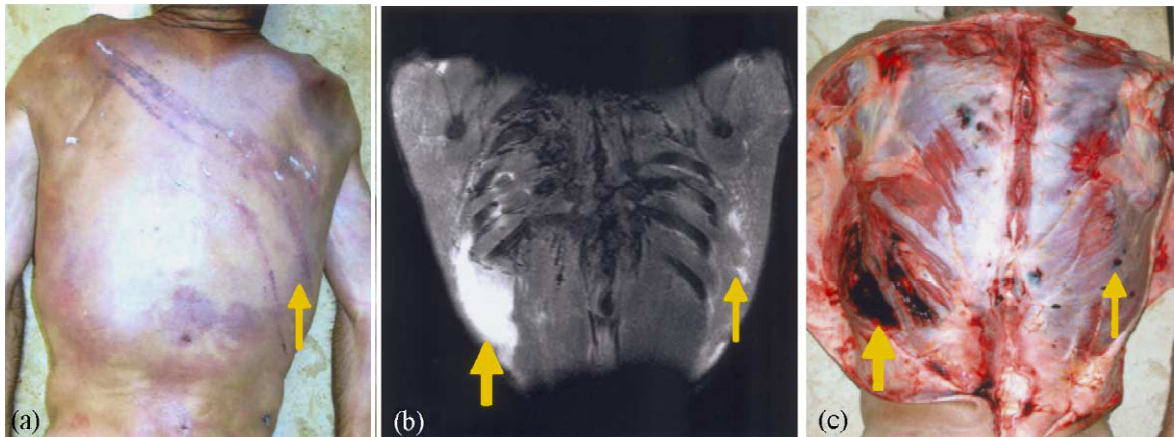


Figure-3

(a) external inspection shows haemorrhages on skin at back side of body (b) MR image of body, which describe 8-10th thoracic vertebrae (c) Example of traditional autopsy, subcutaneous haemorrhages indicate by thin arrow, thick arrow shows soft tissue haematoma at left side¹⁴

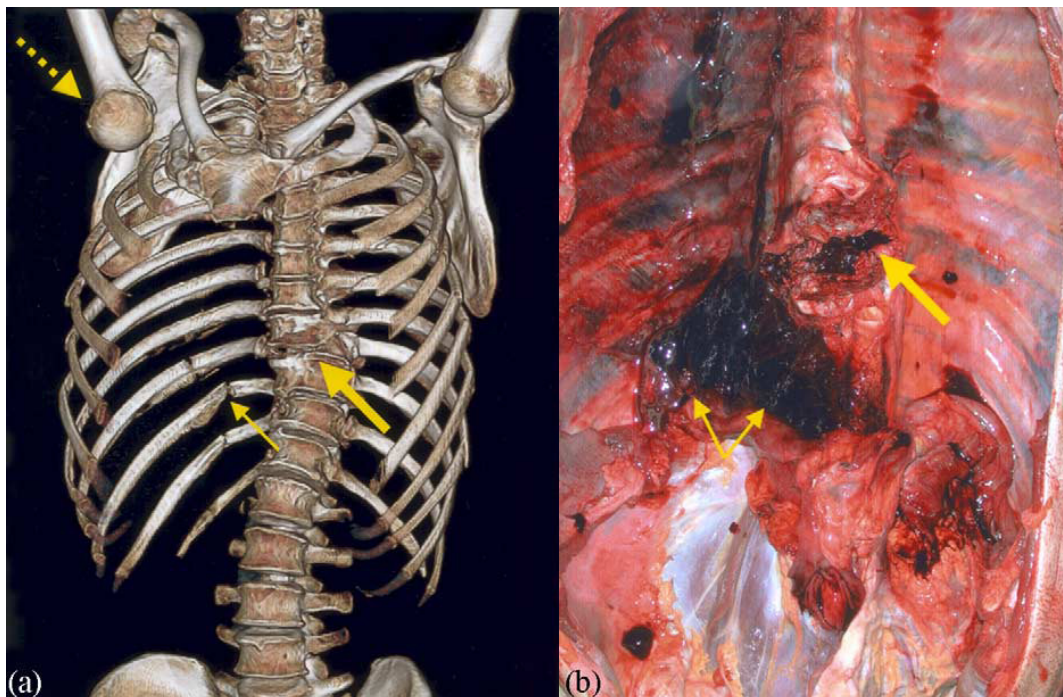


Figure-4

(a) MSCT, three-dimension model of bones without sternum and ventral parts¹⁴
(b) Autopsy image around the soft tissue of fractured vertebrae, para-vertebral extra-pleura haemorrhage¹⁴

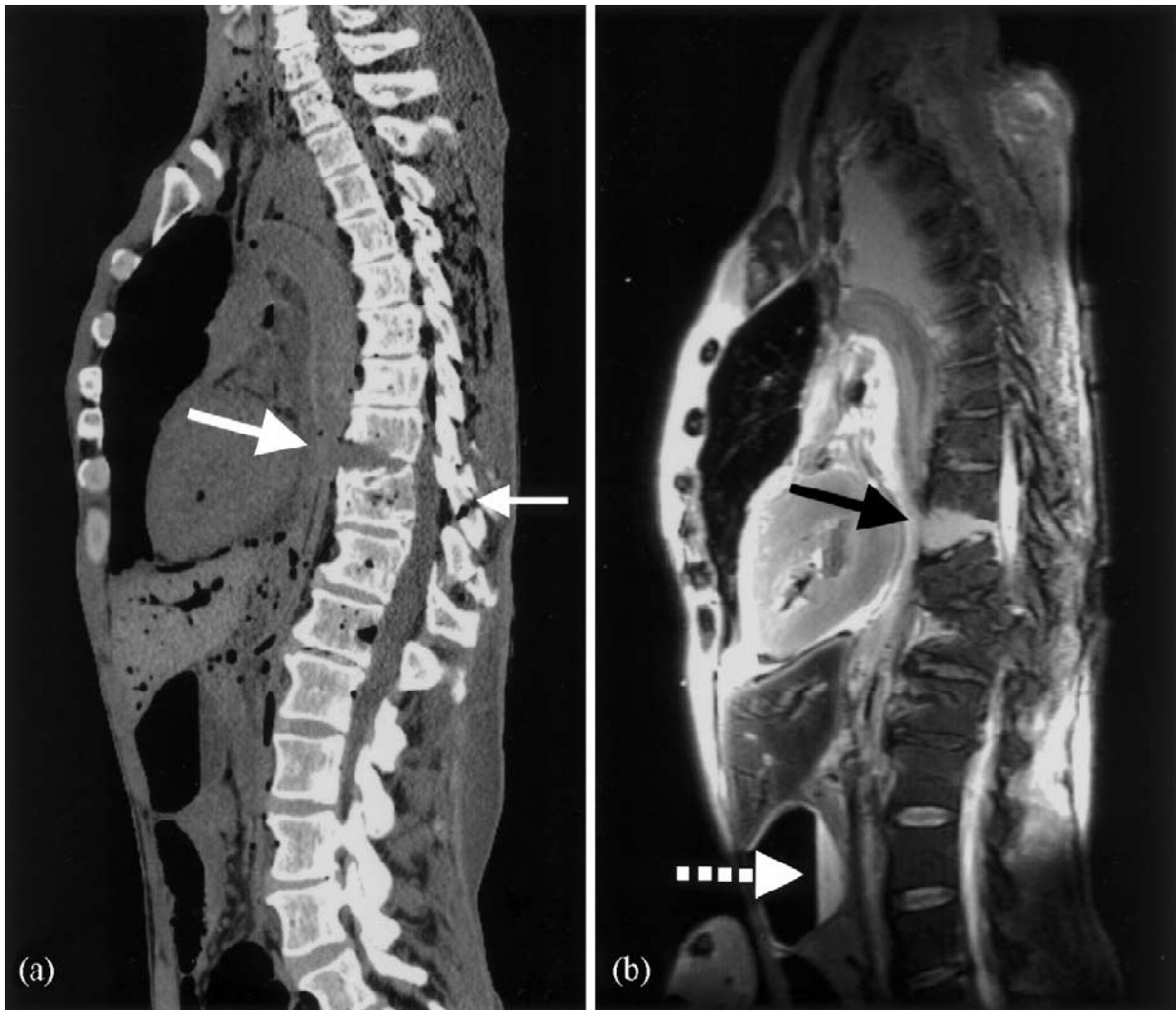

Figure-5
(a) MSCT rupture of aorta and fracture of vertebrae¹⁴.
(b) Dotted line fluid in stomach¹⁴.

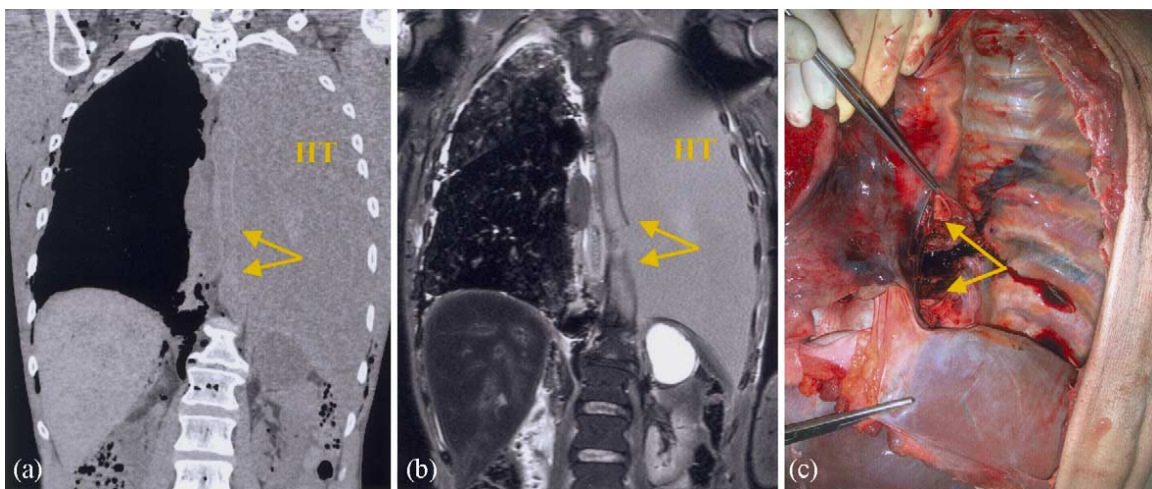


Figure-6
Image a, b and c is followed by MSCT, MRI and autopsy. All picture shows complete rupture of aorta¹⁴.

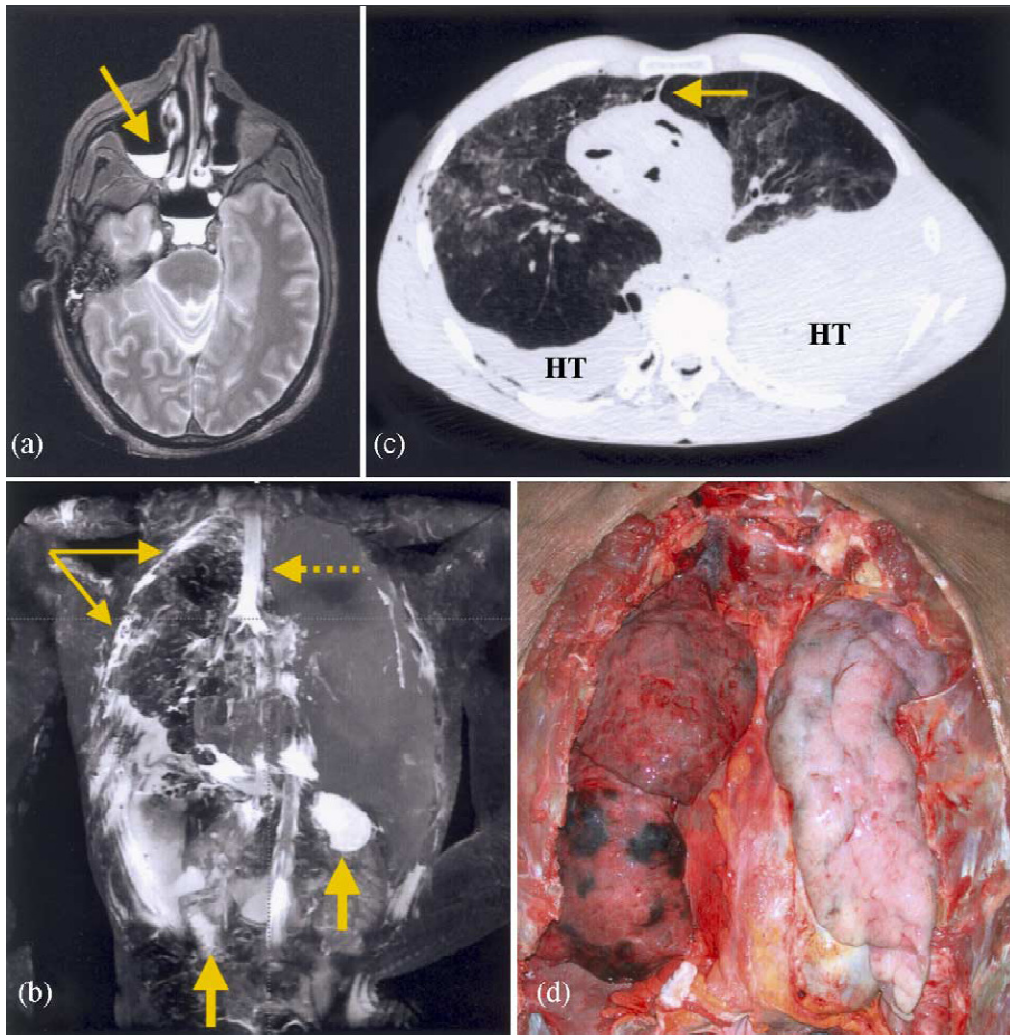


Figure-7

(a) Fluid in the paranasal cavities in axial planes (b) MRI Fluid in the stomach and duodenum (c) The front edges of the lungs (d) Emphysema aquosum at autopsy lungs and thorax cavities¹⁴




Figure-8 (a, b)

Diatom *Cyclotella cyclopuncta* found in lung tissue & water sample of lake¹⁴

Conclusion

The aim of this essay was to evaluate importance of virtopsy. To support this question we looked at first history and evolution of this technique and shown how it became improved due to contribution of individual research projects with time. Then additions of different-different new technologies have great contribution to support this technique and all this technologies give major contribution to lead traditional technologies with different angles. Then this essay talked about advantages of virtopsy but also disadvantages. Then this writing work present limitations of traditional autopsy. Case study of 53 year old swimmer case was with suitable example of autopsy and various virtopsy (CT, MRI and Microscopic images). Finally we discussed main observation of this writing work to lead importance of virtopsy. Whatever Predication and aspects of virtopsy are endless now and in future but I try my best to compose lots of information at one place in brief because area of imaging technology is very big.

References

1. Levy D.A. et al., Virtual Autopsy: Preliminary Experience in High-Velocity Gunshot Wound Victims. Radiological Society of North America (RSNA) Publications, *Radiology*, **240**, 522-528 (2006)
2. Saric D. et al., Application of Computed Tomography in Human Body Injuries. University of Osijek, Mechanical Engineering, Croatian Association of Production Engineering, Zagreb (CIM), (2005)
3. Stawicki S.P. et al., Post-mortem use of advanced imaging techniques : Is autopsy going digital, A Quarterly Publication of OPUS 12 Foundation: Columbus, USA., **2(4)**, 17-26 (2008)
4. Koo Y.K., The autopsy is dead. Pathological Society, University College London, (2010)
5. Thali J.M. et al., Forensic veterinary radiology: Ballistic-radiological 3D computer tomographic reconstruction of an illegal lynx shooting in Switzerland. *Elsevier : Forensic Science International*, **117**, 63-66 (2007)
6. Thali J.M. et al., VIRTOPSY – The Swiss virtual autopsy approach, *Elsevier: Legal Medicine*, **9**, 100-104 (2007)
7. Dirnhofer R., Virtobot, mobile and stationary systems for a minimally invasive autopsy, Forim-X AG: University of Berne, Switzerland (2003)
8. Grabherra S. et al., Angiofil : A novel radio-contrast agent for post-mortem microangiography, *Proc. of SPIE Digital Library*, **7078 (70781O)**, 1-8 (2008)
9. Fisk G., Using Animation in Forensic Pathology and Science Education. Lab medicine, *Americus, GA* **39(10)**, 587-591 (2008)
10. Campobasso C.P., Falamingo R. and Vinci F., Ballistic Wounds and Shooting Reconstruction : Current Challenges for Forensic Pathologists in Criminal Investigations, Shunderson Communications, *Inc The Forensic Scientist Online Journal*, **13-5-020907/030524**, (1-5) (2003)
11. Inman K. and Rudin N, Principles and Practice of Criminalistics : The Profession of Forensic Science, CRC Press, (2000)
12. Miller T.M., Crime scene investigation, CRC Press, 155-134 (2001)
13. Goumas K. et al., Acute ischemic colitis during scuba diving: Report of a unique case, *World Journal of Gastroenterology Press*, **14(20)**, 3262-3265 (2008)
14. Aghaye E. et al., Fatal steamer accident; blunt force injuries and drowning in post-mortem MSCT and MRI, *Elsevier: Forensic Science International*, **152**, 65-71 (2005)
15. Archer M. et al., The Review : Three dimensional perspectives on post mortem CT scanning: impressions of a pathologist, radiologist and forensic technician, Victorian Institute of Forensic Medicine: Australia, **4(2)**, 1-16 (2006)
16. Burgess W.A. R., R.H. Practical aspects of rape investigation: a multidisciplinary approach. London: CRC press, (2009)
17. D'Apuzzo, N. Human, Body Measurement Publication of Homometrica Consulting, Switzerland, **1(2)**, 1-6 (2005)
18. McCormack J. and Slaght J., Extended Writing and Research Skills : Course Book, Southern court, Reading : Garnet publishing ltd, (2009)
19. Germerott T. et al., A new approach in virtopsy: Post-mortem ventilation in multislice computed tomography, *Elsevier: Legal Medicine*, **12**, 276-279 (2010)
20. Grabherr P. et al., Estimation of sex and age of virtual skeletons: A feasibility study, *European Society of Radiology Journal : Austria*, **19**, 419-429 (2009)
21. Jackson A.R.W. and Jackson M.J., Forensic Science, Essex : Pearson Education Limited, (2008)
22. Khairul A.A. and Mohd F.S., Technological innovation and firm development : The case of infovalley digital autopsy system commercialisation, *Asian Academy of Management Journal: Malaysia*, **13(2)**, 79-109 (2008)
23. Levy D.A. et al., Radiology, Department of Radiologic Pathology, Armed Forces Institute of Pathology, Alaska and Fern Streets NW, Washington, **240**, 522-528 (2006)
24. Levy G. et al., Post-mortem Computed Tomography in Victims of Military Air Mishaps : Radiological-Pathological Correlation of CT Findings, *Israel Medical*

- Association Journal (IMAJ)*, **9**, 699-702 (2007)
25. Li R., Forensic Biology, Boca Raton : CRC Press Taylor and Francis Group, (2008)
 26. Michael J.T. et al., Forensic MR Microscopy : Analysis of Blunt Force Trauma in Skin and Subcutaneous Fat Tissue, University Bern, Berne Switzerland, 875 (2003)
 27. Newburn T., Williamson T. and Wright A., Hand Book of Criminal Investigation, Devon : Willan Publishing Ltd, (2007)
 28. Osterburg J.W. and Ward H.R., Criminal Investigation. Cincinnati : Anderson Publishing Co., (2000)
 29. Patowary J.A., Virtopsy : One Step Forward In the Field of Forensic Medicine, *A Review, Journal of Indian Academy of Forensic Medicine*, **30(1)**, 32-36 (2008)
 30. Persson A., Post-mortem Imaging, Center for Medical Image Science and Visualization (CMIV) publications Linköping University, **12**, 15 (2009)
 31. Peter and White, Crime scene to court, Cambridge: The Royal society of Chemistry, (2004)
 32. Richard and Saferstein, Criminalistics : An introduction to forensic science, Upper Saddle River, N.J: Pearson Prentice Hall, (2007)
 33. Saferstein R., Criminalistics : An introduction to forensic science, Boston, Mass; London : Pearson Education (2011)
 34. Townley L and Ede R., Forensic Practice in criminal case, London : the Law Society (2004)